



José Alcides Almeida de Arruda, Emanuel Sávio Andrade, Richard Alonso Andrade, José Ricardo Dias Pereira, Gerhilde Callou

## Vaskularna malformacija na licu: rijedak slučaj praćen 18 godina

### Vascular Malformation of the Face: a Rare Case with Follow-up of 18 Years

Zavod za oralnu i maksilofacijalnu patologiju Sveučilišta Pernambuco, Brazil  
Department of Oral and Maxillofacial Pathology, University of Pernambuco, PE, Brazil

#### Sažetak

**Svrha rada:** Vaskularne malformacije strukturne su anomalije krvnih žila. Prisutne su od rođenja i ostaju cijeli život. Mogu se klasificirati prema vrsti žila koje zahvaćaju. Tako su *vinski madeži* vaskularne malformacije koje obilježava povećan broj ektatičnih žila u dermalnom vaskularnom pleksusu, a mogu se nalaziti na bilo kojem dijelu tijela, uključujući i područje glave i vrata. Tijekom godina većina tih mrlja potiče hipertrofiju mekog tkiva, pa taj rast može uzrokovati tešku deformaciju lica. **Materialijali i metode:** U ovom radu opisan je rijedak slučaj divovske proliferativne vaskularne anomalije koja je nastala od *vinskog madeža* na licu. **Rezultati:** U prikazu se naglasak stavlja na kontinuirani i proliferativni rast lezije koja je praćena 18 godina te na poteškoće pri utvrđivanju dijagnoze zbog njezine složenosti i dimenzije te okolnosti povezanih s lošim socijalno-ekonomskim statusom pacijenta. **Zaključak:** Opisujuemo rijedak i neuobičajen slučaj divovske proliferativne vaskularne malformacije koja potječe od *vinskog madeža* na licu.

**Zaprimljen:** 1. lipnja 2017.**Prihvaćen:** 19. listopada 2017.

#### Adresa za dopisivanje

José Alcides de Arruda, DDS, MsC  
Department of Oral and Maxillofacial Pathology  
University of Pernambuco, PE, Brazil  
alcides\_almeida@hotmail.com

#### Ključne riječi

vaskularna malformacija, vinski madež, krvne žile; lice

#### Uvod

Vaskularne malformacije strukturne su anomalije krvnih žila. Prema definiciji, prisutne su od rođenja i ostaju tijekom cijeloga života. Mogu se klasificirati prema vrsti zahvaćenih krvnih žila (kapilarne, venske, arteriovenske) i hemodinamskim obilježjima (1). *Vinski madež* je kongenitalna kapilarna malformacija koja se obično nalazi u području glave i vrata oko 0,3 posto novorođenčadi (2). Tijekom godina većina tih mrlja završava hipertrofijom mekog tkiva, pri čemu taj rast može uzrokovati tešku deformaciju lica (3 - 5).

S obzirom na sve navedeno, cilj ovoga rada bio je opisati neobičan slučaj proliferativne vaskularne anomalije koja je nastala od *vinskog madeža* na licu. Ovaj slučaj zanimljiv je zato što je bilo moguće pratiti ga 18 godina, te zbog kontinuiranog i ekspanzivnog rasta vaskularne malformacije, što je rezultiralo značajnom deformacijom lica.

#### Prikaz slučaja

Šezdesetogodišnji muškarac, poljski radnik iz sjeveroistočne regije Brazila, radio je izložen sunčevoj svjetlosti još od svoje desete godine. Pacijent je naveo da je rođen s tamnom ljubičastom mrljom na gornjem dijelu lica, bez po-

#### Introduction

Vascular malformations are structural anomalies of the blood vessels. By definition, they are present at birth and persist throughout life. These malformations can be classified according to the type of vessel involved (capillary, venous, arteriovenous) and to hemodynamic characteristics (1). Port-wine stain (PWS) is a congenital capillary malformation commonly found in the head and neck region, which is observed in approximately 0.3% of newborns (2). Over time, most of these stains result in soft tissue hypertrophy and this growth can cause severe facial deformity (3 - 5).

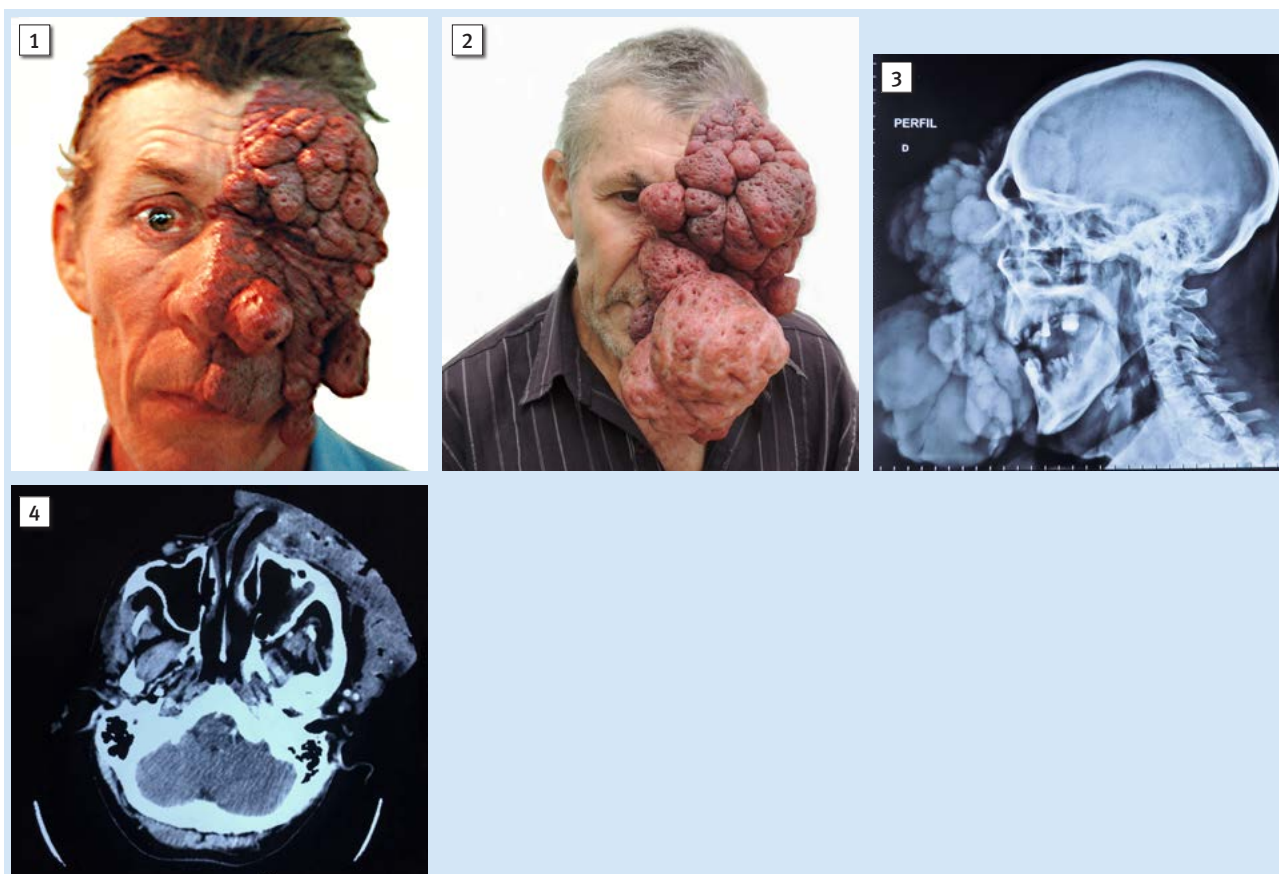
In view of the above considerations, the objective of this study was to describe an unusual case of a proliferative vascular anomaly arising from a PWS on the face. This case is interesting because of the possibility of follow-up for 18 years, its continuous and expansive growth, and the proliferation of the vascular malformation resulting in significant facial deformity.

#### Case Report

A 60-year-old male, rural worker from the Northeastern region of Brazil has been working outdoors exposed to sunshine since he was a 10 year-old boy. The patient reported having been born with a deep purple stain on the upper part

vezane obiteljske anamneze. Kao odrasloj osobi dijagnosticiran mu je *vinski madež* na lijevoj strani lica koji se prostirao uz oftalmološku granu trigeminalnog živca. U 42. godini bilo je očito da je riječ o proliferaciji tumora koji je uključivao oči, nos i gornju usnicu (slika 1.). Trenutačno, u dobi od 60 godina, pacijent je imao tumor vaskularnog podrijetla u lijevom gornjem dijelu lica koji je na početku buknuo iz *vinskog madeža*. Novotvorina je rasla tijekom 18 godina, a obuhvaćala je veliku površinu – od gornje trećine lica do gornje usne, ne prelazeći granicu središnje linije lica i uha. Tumor je stvarao velike, grube crvene režnjeve različitih veličina i širio se u različitim ravninama, ovisno o proliferaciji. Režnjevi su rasli u obliku sjajnih lobularnih i peteljkastih tvorbi promjera približno 20 cm i bili su blisko povezani, čime je bio ograničeno otvaranje očiju te se deformirao nos (slika 2.). Pacijent se žalio na ozbiljne probleme jer mu se pojavljivala želja za samoubojstvom, patio je od glavobolja, vrtoglavice te vrućeg i hladnog osjećaja pulsiranja u zahvaćenoj regiji. Kraniogram

of the face, no correlated family history. As an adult, a PWS was diagnosed on the left side of the face, extending along the ophthalmic branch of the trigeminal nerve. At age 42, a tumor proliferation was evident, which involved the eyes, nose and upper lip (Figure 1). Currently, the patient is 60 years old and he presented with an exuberant tumor of vascular origin in the left upper part of the face, which was initially associated with a PWS on his hemi face. The tumor has been growing over a period of 18 years, involving an extensive area from the upper facial third to the upper lip and respecting the limits of the midline of the face and ear. The tumor reached extensive proportions, forming large, rough, red lobes of varying sizes and extending in different planes depending on the growth of these proliferations. These lobes grew as shiny, lobular, pedunculated masses measuring approximately 20 cm in diameter, joined closely together, thus reducing eye opening and deforming the nose (Figure 2). The patient felt embarrassed and suicidal and was complaining about headache,



**Slika 1.** Pacijent u dobi od 42 godine (fotografija snimljena 1998.) – frontalni prikaz lica pokazuje proliferaciju tumora koji zahvaća oko, nos i gornju usnicu

**Figure 1** Patient at age 42 (image taken in 1998) Frontal view of face showing tumor proliferation with involvement of eye, nose and upper lip.

**Slika 2.** Pacijent u dobi od 60 godina – uočava se bujanje tumora vaskularnog podrijetla lijevo na gornjem dijelu lica koji se na početku manifestirao kao vinski madež

**Figure 2** Patient at age 60. Note the exuberant tumor of vascular origin in the left upper part of the face, initially associated with a port-wine stain on his hemi face.

**Slika 3.** Kraniogram pokazuje multiple mekotkivne čvoraste tvorbe na licu i odsutnost intrakranijalnih patoloških kalcifikacija

**Figure 3** Cranial X-ray showing multiple soft tissue nodular images of the face and the absence of intracranial pathological calcifications.

**Slika 4.** Kompjutorska tomografija s kontrastom pokazuje koštanu strukturu normalne morfologije i višestruke okrugle lezije s gustim mekim tkivom koje tvori klasterne smještene u koži i u potkožnom staničnom tkivu lica i temporoparijetalne regije

**Figure 4** Contrast-enhanced Computed Tomography showing bone structures of normal morphology and multiple round lesions, with soft tissue densities forming clusters, located in the skin and subcutaneous cellular tissue throughout the face and temporoparietal regions.

je otkrio više nodularnih tvorbi mekoga tkiva na licu i odsutnost intrakranijalnih patoloških kalcifikacija (slika 3.). Kompjutoriziranom tomografijom s kontrastom identificirani su oblici klastera čvrstih čvorova lociranih u koži i u potkožnom staničnom tkivu lijeve temporoparijetalne regije, bez invazije na kosti (slika 4.). Tim liječnika i stomatologa zatražio je kliničke i komplementarne pretrage koje su upućivale na dijagnozu *vinskog madeža*, malformaciju koja je perzistirala i dosegula velike razmjere tijekom pacijentova života.

## Rasprava

*Međunarodno društvo za proučavanje vaskularnih anomalija* takve promjene klasificira kao vaskularne tumore i vaskularne malformacije (6). Ti entiteti mogu se dijagnosticirati kliničkim instrumentima. No u neizvjesnim slučajevima kada dijagnoza nije sigurna, od pomoći mogu biti obojeni Dopplerov uređaj, angiografija i biopsija (7, 8). Takav pristup mogao bi pridonijeti dijagnostičkoj preciznosti, ali naš je pacijent odbijao pretrage u zatvorenim strojevima.

*Vinske mrlje* najprije se pojavljuju kao ružičaste makule koje se povećavaju kako dijete raste dok ne dosegnu stupanj hipertrofije mekoga tkiva koja može uzrokovati nodule, pa čak i tumore (4, 5). Unatoč nedostatku istraživanja koja povezuju izloženost suncu i proliferaciju vaskularnih malformacija, činjenica da je pacijent bio poljski radnik izložen cijelog života sunčevoj svjetlosti, povećava mogućnost da upravo to može biti etiološki čimbenik koji je potaknuo znatan rast kongenitalne tvorbe (2). U medicinskoj literaturi nisu dostupni nikakvi podaci o ovoj vrsti lezija koje nastaju iz *vinskih madeža* i razvijaju se u takvim razmjerima.

Na temelju tih nalaza i uz pomoć multidisciplinarnog tima koji je bio uključen u slučaj, može se zaključiti da je pacijent imao kongenitalnu krvožilnu malformaciju koja je dosegula značajne razmjere tijekom života. Taj je poremećaj vjerojatno bio arterijskog podrijetla, jer su venske malformacije asimptomatske. Pacijent je cijeli život imao osjećaj pulsiranja na zahvaćenom području. No zbog nemogućnosti podvrgavanja angiografiji, lezija se najbliže može dijagnosticirati kao arterijska malformacija, jer su one venske obično tamnoplave i pacijenti rijetko imaju simptome (7). Proliferativne malformacije kod našeg pacijenta bile su pretežno crvene.

Prognoza i liječenje vaskularnih malformacija koje nastaju iz *vinskih madeža* kontroverzni su. Cerrati i suradnici u svojem radu iz 2014. smatraju da je terapija sigurna i učinkovita, uz minimalno povećani rizik od krvarenja, jer se malformacija uglavnom nalazi u površinskim tkivima (3). No naš je pacijent imao velike lezije (> 20 cm), pa bi tehnike liječenja opisane u literaturi svakako bile izazov s povećanim rizikom od smrti.

dizziness and a hot, cold and pulsatile feeling in the affected region. A cranial X-ray revealed multiple nodular soft tissue images on the face and the absence of intracranial pathological calcifications (Figure 3). Contrast-enhanced computed tomography identified soft tissue densities formed by clusters of solid nodules located in the skin and subcutaneous cellular tissue of the left /temporoparietal region without bone invasion. (Figure 4). A team of physicians and dentists requested clinical and complementary exams, which suggested the diagnosis of a PWS, a malformation that persisted and reached large proportions during the life of the patient.

## Discussion

The International Society for the Study of Vascular Anomalies classified vascular anomalies into vascular tumors and vascular malformations (6). These entities can be diagnosed by clinical means. However, in uncertain cases, color Doppler, angiography and biopsy can be of help when the diagnosis is not certain (7, 8). This approach could contribute to diagnostic precision, but our patient was extremely reluctant to undergo examinations in closed devices.

Port-wine stains first appear as a pink macule that progresses in size as the child grows, reaching a stage of soft tissue hypertrophy that can cause nodules and even tumors (4, 5). Despite the scarcity of studies correlating sun exposure with the proliferation of vascular malformation, the fact that the patient was a rural worker exposed to sunlight throughout his life, raises the possibility that the sun exposure could be an etiological factor that promoted considerable growth of the congenital PWS reported by the patient (2). No reports of this type of lesion, which arise from a PWS and develop to such a great extent, are available in the medical literature.

Based on these findings and with the help of the multidisciplinary team involved in the case, it can be concluded that the patient has a congenital vascular malformation that reached considerable proportions during his life. This malformation was probably of arterial nature since venous malformations are asymptomatic. The patient reported a constant pulsatile feeling on the affected region throughout his life. However, due to the patient's unwillingness to take an angiography, it is best to diagnose the lesion as an arterial malformation, since patients with venous malformations are usually deep blue in color and they seldom report symptoms (7). The proliferative malformations in our patient were essentially red.

The prognosis and treatment of vascular malformations arising from PWS is controversial. In 2014, the treatment was considered safe and effective by Cerrati et al, with only a minimally increased risk of bleeding, since the malformation is mainly located in superficial tissues (3). However, our patient had extensive lesions (> 20 cm), therefore, the treatment techniques described in the literature would certainly be a great challenge for our healthcare team, with an increased risk of death.

## Zaključak

Ukratko, riječ je o prikazu rijetkog i neobičnog slučaja ve- like proliferativne vaskularne malformacije koja je nastala od vinskog madeža na licu. Slučaj je zanimljiv zbog 18-godišnjeg praćenja i kontinuiranog i proliferativnog rasta tvorbe. Poštu- jući bioetičko načelo autonomije, zdravstveni tim prihvatio je odluku pacijenta da se ne liječi.

## Sukob interesa

Autori nisu bili u sukobu interesa.

## Conclusions

In summary, this is a rare and unusual case of a giant pro- liferative vascular malformation arising from a PWS on the face. The case calls for attention because of the fol- low-up period of 18 years and its continuous and prolifera- tive growth. Respecting the bioethical principle of autonomy, the healthcare team accepted the patient's decision not to un- dergo treatment.

## Conflict of interest

None.

### Abstract

**Objective:** Vascular malformations are structural anomalies in the blood vessels. They are present at birth and persist throughout life. These malformations can be classified according to the type of ves- sel involved. A port-wine stain is a vascular malformation characterized by an increased number of ec- tatic vessels in the dermal vascular plexus, which can be found in any part of the body, including the head and neck region. Over time, most of these stains result in soft tissue hypertrophy and this growth can cause severe facial deformity. **Materials and Methods:** This study describes a rare case of a giant proliferative vascular anomaly arising from a port-wine stain on the face. **Results:** The report highlights the continuous and proliferative growth of the malformation observed after follow-up of 18 years, as well as the difficulty in establishing the diagnosis due to the complexity and dimension of the lesion and the conditions related to the patient's low socioeconomic status. **Conclusions:** We have described a rare and unusual case report of a giant proliferative vascular malformation arising from a Port-wine stain on the face.

**Received:** June 1, 2017

**Accepted:** October 19, 2017

### Address for correspondence

José Alcides de Arruda, DDS, MSc  
Department of Oral and Maxillofacial  
Pathology  
University of Pernambuco, PE, Brazil  
alcides\_almeida@hotmail.com

### Key words

Vascular Malformations; Port-Wine  
Stain; Blood Vessels; Face

## References

1. Adams DM, Lucky AW. Cervicofacial vascular anomalies. I. Hem- angiomas and other benign vascular tumors. *Semin Pediatr Surg.* 2006 May;15(2):124-32.
2. van Drooge AM, Beek JF, van der Veen JP, van der Horst CM, Wolk- erstorfer A. Hypertrophy in port-wine stains: prevalence and pa- tient characteristics in a large patient cohort. *J Am Acad Dermatol.* 2012 Dec;67(6):1214-9.
3. Cerrati EW, O TM, Binetter D, Chung H, Waner M. Surgical treat- ment of head and neck port-wine stains by means of a staged zonal approach. *Plast Reconstr Surg.* 2014 Nov;134(5):1003-12.
4. Orten SS, Waner M, Flock S, Roberson PK, Kincannon J. Port-wine stains: An assessment of 5 years of treatment. *Arch Otolaryngol Head Neck Surg.* 1996 Nov;122(11):1174-9.
5. Klapman MH, Yao JF. Thickening and nodules in port-wine stains. *J Am Acad Dermatol.* 2001 Feb;44(2):300-2.
6. MeSH Browser [database on the Internet]. ISSVA classification for vascular anomalies. International Society for the study of vas- cular anomalies (Approved at the 20th ISSVA Workshop). 2014. Available from: <http://www.issva.org/classification>.
7. Fowell C, Vereza Linares C, Jones R, Nishikawa H, Monaghan A. Ve- nous malformations of the head and neck: current concepts in management. *Br J Oral Maxillofac Surg.* 2017 Jan;55(1):3-9.
8. McCafferty IJ, Jones RG. Imaging and management of vascular malformations. *Clin Radiol.* 2011 Dec;66(12):1208-18.