

Ahmed Abulwefa¹, Hrvoje Brkić², Zvonimir Kaić³

Razlike u erupcijskom kutu palatinalno impaktiranih očnjaka kod pacijenata s Klinefelterovim sindromom: retrospektivno istraživanje na ortopantomogramima

Differences in the Eruption Angle of Palatally Displaced Canines in Klinefelter Syndrome: a Retrospective Study on Panoramic Radiographs

- ¹ Zavod za ortodontiju, pedodontiju i preventivnu stomatologiju Stomatološkog fakulteta Sveučilišta u Tripoliju, Libija
Department of Orthodontics, Pedodontics and Preventive Dentistry, Faculty of Dental Medicine and Oral Surgery, Tripoli University, Libya
- ² Zavod za dentalnu antropologiju Stomatološkog fakulteta Sveučilišta u Zagrebu i Klinička bolnica Merkur u Zagrebu, Hrvatska
Department of Dental Anthropology, School of Dental Medicine University of Zagreb & Clinical Hospital Merkur in Zagreb, Croatia
- ³ Zavod za dentalnu antropologiju Stomatološkog fakulteta Sveučilišta u Zagrebu, Hrvatska
Department of Dental Anthropology, School of Dental Medicine University of Zagreb, Croatia

Sažetak

Svrha rada: Željelo se istražiti erupcijski kut maksilarnoga očnjaka kod osoba s Klinefelterovim sindromom (KS) kojima je kliničkom procjenom utvrđena velika učestalost palatinalne impakcije toga zuba (PDC). **Ispitanici i metode:** Uzorak se sastojao od 37 muških ispitanika s KS-om u dobi od 20 do 34 godine (srednja dob 27 godina), a kontrolnu skupinu činilo je 78 zdravih muškaraca u dobi od 20 do 27 godina (prosječna dob 23 godine). Za mjerenje erupcijskog kuta korištena je pionirska metoda temeljena na spajanju gonion točaka na ortopantomogramu. **Rezultati:** Srednja vrijednost kuta erupcije kod ispitanika s KS-om bila je povećana u odnosu na kontrolnu skupinu za 10,58° na desnoj strani i 9,69° na lijevoj strani. Razlika između mezoangularnog nagiba impaktiranih očnjaka kod ispitanika s KS-om bila je statistički značajna ($p < 0,01$). Kad je erupcijski kut u kontrolnoj skupini bio povezan s Klinefelterovim sindromom, potvrđena je statistički značajna razlika za odgovarajuću stranu ($P < 0,01$). **Zaključak:** Čini se da razlika između vrijednosti erupcijskih kutova kod ispitanika s KS-om i u kontrolnoj skupini identificira razvojne poremećaje na koje utječe dodatni X kromosom. Go-Go metoda može se upotrijebiti za muške ispitanike ako postoji teškoća u definiranju okluzijske ravnine ili za usporedbu. Korištenjem ove metode vrijednosti kuta erupcije palatinalnih očnjaka ne bi trebale prelaziti 56,74°.

Zaprimljen: 9. svibnja 2017.**Prihvaćen:** 6. studenoga 2017.**Adresa za dopisivanje**

Prof. Dr. Ahmed Abulwefa
Tripoli University
Faculty of Dental Medicine and Oral Surgery
Department of Orthodontic-
Pedodontic-Preventive Dentistry
Tripoli, Libya
abulwefa2009@yahoo.com

Ključne riječi

Klinefelterov sindrom, ektoپیčno nicanje zuba; tvrdo nepce; očnjak; panoramska radiografija; poremećaji spolnih kromosoma

Uvod

Pojam Klinefelterov sindrom (KS) opisuje skupinu kromosomskih poremećaja kod kojih je normalnome muškom kariotipu dodan najmanje jedan X-kromosom. Klasičan oblik najčešći je kromosomski poremećaj kod kojeg postoji jedan dodatni X-kromosom, što rezultira kariotipom 47, XXY. Klinefelterov sindrom najčešći je kromosomski spolni poremećaj – pogađa približno jednog od 500 muškaraca (1). KS je nedovoljno dijagnosticiran kromosomski poremećaj, što rezultira velikim i važnim izazovima kad je riječ o zdravlju i medicinskoj skrbi. Nažalost, dijagnosticira se samo 25 posto očekivanog broja KS-a, a tek manji dio prije puberteta. Rano prepoznavanje i anticipativne mjere iznimno su važni u upravljanju KS-om. Nadomjesna hormonska terapija važan

Introduction

The term Klinefelter syndrome describes a group of chromosomal disorders in which there is at least one extra X chromosome added to a normal male karyotype, 46, XY. The classic form is the most common chromosomal disorder, in which there is one extra X chromosome resulting in the karyotype of 47, XXY. Klinefelter syndrome is one of the most common sex chromosome disorders affecting approximately one in every 500 men (1). Klinefelter syndrome (KS) is an under-diagnosed chromosomal disorder resulting in important challenges for health and medical management. Unfortunately, only 25 % of the expected number of patients with KS are diagnosed and only a minority before the puberty onset. Early identification and anticipatory guidance

je aspekt u liječenju ovog poremećaja koji obično počinje u pubertetu oko dvanaeste godine (2, 3).

Pacijenti s Klinefelterovim sindromom visoki su, s uskim ramenima, širokim bokovima i ginekomastijom, a opisani su i manje specifični fenotipovi (2). Muškarce s KS-om pogađa enhondralni rast baze lubanje koja ima izravan utjecaj na rast čeljusti (1). Oni se također razlikuju s obzirom na kraniofacijalni oblik i morfogenezu (4, 5) te orofacijalnu morfologiju (6). Razlike se očituju u duljem i plićem tvrdom nepcu (7 – 9), većim dimenzijama alveolarnih lukova (7), povećanoj veličini zuba (10, 11) te duljim korijenima zuba kod muškaraca s kariotipom 47, XXY (12, 13). Dosad su zabilježene različite dentalne anomalije, kao što su taurodontizam (13, 14), višestruko impaktirani zubi (15), velika učestalost PDC-a (16) i teške malokluzije (17, 18).

Palatinalno impaktirani očnjaci (PDC) manifestiraju se anomalijom položaja, a čini se da su posljedica poligenetskog, višestruko nasljeđivanja (19). Iako se očnjak razvija visoko u blizini orbite i sinusa, bukalno od korjenova susjednih zuba, 85 posto impaktiranih očnjaka nalazi se palatinalno (20, 21). Odnos palatinalne i bukalne impakcije kreće se od 3 : 1 do 12 : 1 (21, 22).

Ispitivanja genetskog utjecaja usredotočena su na bilateralnu ekspresiju PDC-a, spolnu predispoziciju (23), obiteljsku pojavu (24), dokaze iz područja orofacijalne genetike (25), varijaciju veličine zuba u denticijama s palatinalnom impakcijom očnjaka (26, 27), na povezanost dentalnih i okluzijskih anomalija (28), te na odnos palatinalnog pomaka i maksilarne širine (29).

Za određivanje hoće li se pojaviti impakcije, dostupne su različite metode mjerenja s pomoću sektora i kutova (30 – 32). Različite rendgenske ekspozicije, CBCT i CT mogu pomoći u procjeni položaja očnjaka (33 – 40). Panoramske snimke uglavnom su pouzdane kad je riječ o određivanju položaja impaktiranih zuba u svim trima prostornim dimenzijama, utvrđivanju odnosa prema sredini i susjednim zubima te u procjeni prisutnosti resorpcije (41), uzimajući u obzir da izvor zračenja dolazi iza pacijenta, stoga su pokreti obrnuti.

Cilj ovog istraživanja bio je istražiti razlike između erupcijskog kuta palatinalno impaktiranih očnjaka kod pacijenata s KS-om i kontrolne skupine na ortopantomogramu.

Ispitanici i metode

U ovom retrospektivnom istraživanju proučavali su se ortopantomogrami 69 maksilarnih impaktiranih očnjaka 38 pacijenata s KS-om u dobi od 20 do 34 godine (prosječno 27 godina). Pacijenti su bili dio velikog uzorka hrvatskih pojedinaca s različitim poremećajima spolnih kromosoma koji su ispitani tijekom realizacije istraživačkog projekta *Karakteristike kraniofacijalnog kompleksa u Gonadalovoj disgenezi* od 1991. do 1996., sa svrhom da se analizira njihov dentalni i kraniofacijalni rast i razvoj. Sveukupno je trideset i osmori-

are extremely helpful in managing the patient with KS. Androgen replacement therapy is an important aspect in treating this disorder, which usually starts at puberty, around 12 years of age (2, 3).

Klinefelter syndrome patients are tall. They have narrow shoulders, broad hips, and gynecomastia. Less distinct phenotypes have also been described (2). The KS males are affected by endochondral growth in the cranial base that has a direct influence on jaw growth (1). Males with KS have differences in craniofacial shape and morphogenesis (4, 5), and orofacial morphology (6). The difference was found in increased length of hard palate, which is shallow (7 - 9), larger alveolar arch dimensions (7) increased tooth size (10, 11). An increased growth of the final tooth root length in 47, XXY males was also confirmed (12, 13). So far, different dental anomalies such as taurodontism (13, 14), multiple impacted teeth (15), high prevalence of PDCs (16) and severe malocclusion have been reported (17, 18).

A palatally displaced canine manifests itself through positional anomalies and appears to be a product of polygenic, multifactorial inheritance model (19). Although the canine develops high near the orbit and sinus, and is buccal to adjacent tooth roots, 85% of impacted canines are located palatally (20, 21). The palatal- to-buccal impaction ratio ranges from 3:1 to 12:1 (21, 22).

Traces of genetic influence have focused on bilateral expression of PDC, sex predilection (23), familial occurrence (24), and on argued evidence of orofacial genetic fields (25), on tooth size variation in dentitions with palatal canine displacement (26, 27), on association with dental and occlusal anomalies (28), and on relationship between palatal displacement and the maxillary skeletal width (29).

In order to determine whether impaction will occur, different measurement methods using sectors and angular measurement were devised (30-32). Various radiographic exposures, cone-beam computed tomography and three-dimensional computed tomography can help in evaluating the position of the canines (33-40). In most cases, panoramic views are reliable to localize impacted teeth in all three planes of space, to view the relationship to the midline and adjacent teeth and to evaluate any resorption (41), with the understanding that the source of radiation comes from behind the patient. In this way, the movements are reversed for position.

The aim of this study was to examine the differences of the eruption angle of palatally displaced canines in KS patients and the control group. For this purpose, panorex images were analyzed.

Subjects and methods

This retrospective study examined panoramic radiographs images of 69 maxillary impacted canines in 38 KS patients aged 20-34 (mean 27 years). The patients were part of a large sample of Croatian individuals with various sex chromosome disorders examined within "Characteristics of the Craniofacial Complex in Gonadal Dysgenesis" research project, which was conducted from 1991 to 1996 in order to investigate dental and craniofacial growth and development of the abovementioned population. A total of 38 men with KS (34 karyotype

ci muškaraca dijagnosticiran KS (34 kariotip 47, XXY, jedan kariotip 48,XXX, dva mozaična kariotipa 47, XXYq). Njihovi su kariotipovi utvrđeni u Klinici za ginekologiju i opstetriciju Sveučilišnoga kliničkog centra, Zagreb, Hrvatska. Kariotip je određen citogenetskim testovima, kromosomskom analizom perifernih limfocita i fibroblasta kože. Kontrolna skupina sastojala se od 78 fenotipski zdravih muškaraca u dobi od 20 do 27 godina (prosječno 23 godine), studenata dentalne medicine ili pacijenata Sveučilišne kliničke bolnice te dijela zbirke za isti projekt Zavoda za stomatološku antropologiju Stomatološkog fakulteta u Zagrebu. Ispitanici nisu imali sistemske bolesti povezane s kostima te su imali barem jedan impaktirani maksilarni očnjak. Neki od pacijenata iz kontrolne skupine bili su prije toga podvrgnuti ortodontskoj terapiji. Kriterij za uključivanje u ovo istraživanje bila je prisutnost maksilarnog očnjaka. Zbog toga je jedan pacijent s KS-om isključen zbog ranije ekstrakcije obaju gornjih očnjaka. Informirani pristanak dobiven je od svih pacijenata. Provedbu istraživanja odobrio je Etički odbor.

Zbog poteškoća u pronalaženju izvorne okluzalne ravnine kod muškaraca s kariotipom 47,XXY (42), kut erupcije gornjega očnjaka izmjeren je s pomoću pionirske geometrijske metode na temelju spajanja točaka gonion na ortopantomogramu. Sve rendgenske snimke snimljene su istim uređajem. Ravnalo, šestar, ploča i olovka debljine 0,5 mm korišteni su na acetatnoj foliji A4 na negatoskopu. Najprije su precrtani oblici mandibule i trajnih maksilarnih očnjaka. Određene su Go-točke desne i lijeve strane te povezane linijom. Virtualna središnja linija čeljusti (S) određena je geometrijski šestarom kako bi se izmjerila duljina spojne linije između goniona. Nakon mjerenja ravnalom, polovina udaljenosti uzeta je na šestaru koji je smješten u Go-točku desne i lijeve strane kako bi se nacrtala točka iznad i točka ispod Go-Go linije. Spajanjem ovih točaka dobivena je virtualna središnja linija čeljusti (S).

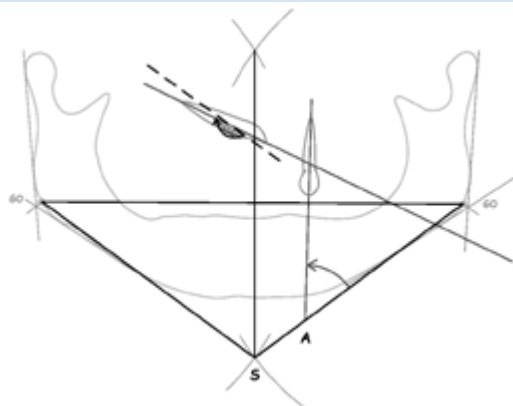
Aksijalna crta izvučena je s vrha korijena očnjaka preko točke incizalne kvržice krune do referentne linije između Go-točaka i virtualne središnje linije za svaku stranu. Izmjereni kut bio je otvoren distalno (slika 1.).

Sredine i standardne devijacije za obje skupine izračunate su za sve vrijednosti statističkim paketom za društvene znanosti (Mann-Whitneyjev U-test). Razlike između dviju skupina određene su neparametrijskim Mann Whitneyjevim U-testom.

constitution 47, XXY, one karyotype constitution 48, XXXT, two with mosaic karyotype constitution 47, XXYq), were examined and diagnosed. Their karyotypes had been determined at the Clinic for Gynecology and Obstetrics, University Clinical Centre, Zagreb, Croatia. The karyotype was determined by cytogenetic tests and a chromosome analysis of peripheral lymphocytes and skin fibroblasts. The control group consisted of 78 phenotypically healthy no syndromic males aged 20 -27 (mean 23 years) dental students or patients of the University Clinical Hospital and part of the collection used for the same project from the Department of Dental Anthropology, School of Dental Medicine, University of Zagreb. All individuals had no systemic disease related to bones, and they presented with at least one maxillary impacted canine. Some subjects from the control group had previously undergone orthodontic treatment. The selection criterion for the inclusion in the present study was the presence of maxillary canine. Therefore, one patient with KS was excluded because of earlier extraction of both maxillary canines. Informed consent was obtained from all participants in the study. Ethical approval was obtained from Ethics Committee prior to commencement of the study.

Due to difficulties in locating the original occlusal plane position in 47, XXY males (42), the eruption angle of the maxillary canine was measured with the use of a pioneer geometrical method based on construction of Gonion points on panoramic radiographs. Panoramic radiographs were taken by panoramic scanning dental imaging device- Orthopantomograph. A ruler, bow divider, tracing plate, and tracing pencil 0.5 mm lead was used on an acetate tracing foil A₄ on a negatoscope. Firstly, the form of the mandible and the maxillary permanent canines were traced out. The Go point was constructed and determined on tracing paper for right and left side and it was connected by a line. The virtual midline of the jaw (S) was determined geometrically, using a bow divider to measure the length of the connection line between the gonions. After measuring the line on the ruler, one half of the distance was used with the bow divider centralized on the Go point of right, subsequently of left side to draw a point above and a point below the Go-Go line. The intersection of these points results in virtual midline of the jaw (S).

The axial line was drawn from the tip of the canine root across the point of the incisal cusp of the canine crown to the reference line between the Go - point and the virtual midline



Slika 1. Go – Go točke – S: Virtualna medijalna linija. A: Aksijalna linija očnjaka, izmjereni kut otvoren je distalno; desni PDC ima znatno povećan erupcijski kut

Figure 1 Go – Go points. S: Virtual Medline. A: axial line of canine, the measured angle is opened distally. The right PDC shows a highly increased eruption angle

of the jaw for each side. The measured angle was opened distally (Figure 1).

The means and standard deviations for the two groups were calculated for all values using the Statistical Package for Social Sciences (Mann-Whitney U Test). The differences between the two groups were determined using a Non-parametric Mann Whitney U Test.

Rezultati

Među ispitanicima s KS-om, 69 očajnika pronađeno kod 37 pacijenata (pet je izvađeno prije istraživanja). Ustanovljeno je da je sedam osoba s KS-om bilo pogođeno PDC-om; osam očajnika bilo je impaktirano palatinalno. Analiza distribucije PDC-a pokazala je da su na lijevoj strani bile pogođene tri osobe, na desnoj strani također tri, a obostrano jedan pacijent (nema značajne razlike s obzirom na strane). Ni u jednoj skupini očajnici nisu bili impaktirani bukalno. Statistički izmjereni erupcijski kutovi PDC-a kod pacijenata s KS-om imali su veću varijabilnost i distribuciju (slika 2.). Interval pouzdanosti od 95 posto utvrđen je za srednju vrijednost za svaku skupinu, pri čemu je za desnu stranu kod paci-

Results

69 maxillary canines were found in 37 KS subjects, (five maxillary canines were missing before the examination). Seven KS individuals were found to be affected with PDC; eight canines were displaced in the palatal side. The distribution of unilateral and bilateral subjects in the PDC sample showed that three individuals were affected on the left side, three individuals were affected on the right side, and one patient had PDC on both sides (no significant difference considering the sides). No buccally displaced canines were found in both groups. Statistically, the eruption angle measurements of PDC in the KS patient were marked by a greater variability and distribution (Figure 2). A 95% confidence inter-

Tablica 1. Opis uzoraka prema lijevoj i desnoj strani pacijenata s KS-om i kontrolne skupine
Table 1 Description of the samples according to right and left sides of KS patients and controls

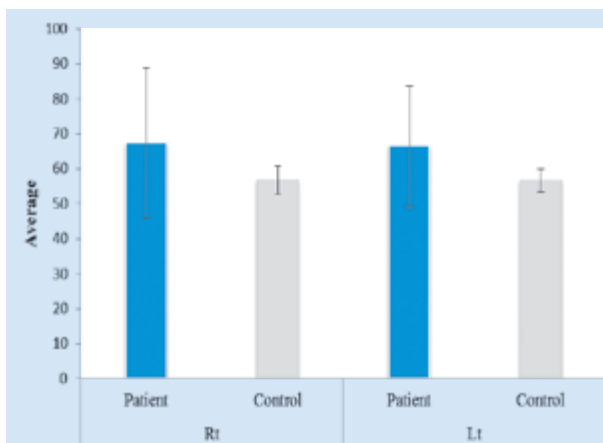
Mjerenje • Measurement		Strana • Side	D • Rt		L • Lt	
			Pacijent • Patient	Kontrola • Control	Pacijent • Patient	Kontrola • Control
Sredina • Mean			67.32	56.74	66.38	56.69
95 % interval pouzdanosti • 95% Confidence Interval for Mean	Donja granica • Lower Bound		60.14	55.86	60.64	55.96
	Gornja granica • Upper Bound		74.51	57.63	72.11	57.42
Std. devijacija • Std. Deviation			21.551	3.939	17.204	3.229
Minimum			44	43	42	44
Maksimum • Maximum			180	80	162	76

Tablica 2. Usporedba pacijenata s KS-om i kontrolne skupine na desnoj strani
Table 2 Comparison of KS patients and controls of the right side

Mjerenje • Measurement		Strana • Side	D • Rt		L • Lt	
			Pacijent • Patient	Kontrola • Control	Pacijent • Patient	Kontrola • Control
Sredina • Mean			67.32	56.74	66.38	56.69
95 % interval pouzdanosti • 95% Confidence Interval for Mean	Donja granica • Lower Bound		60.14	55.86	60.64	55.96
	Gornja granica • Upper Bound		74.51	57.63	72.11	57.42
Std. devijacija • Std. Deviation			21.551	3.939	17.204	3.229
Minimum			44	43	42	44
Maksimum • Maximum			180	80	162	76

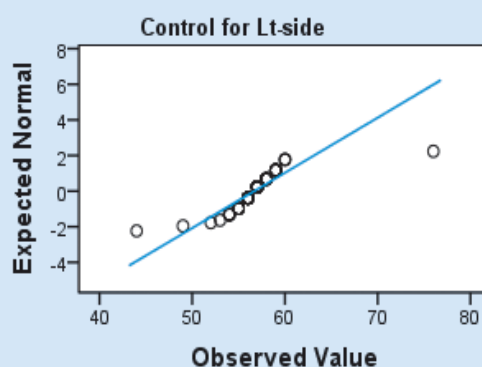
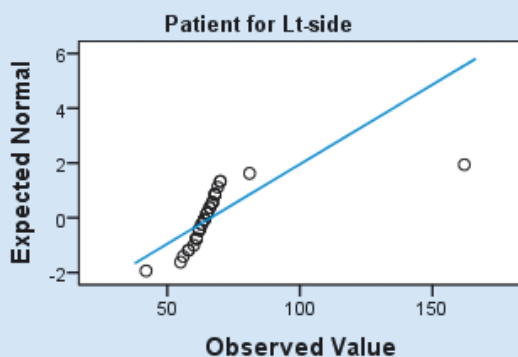
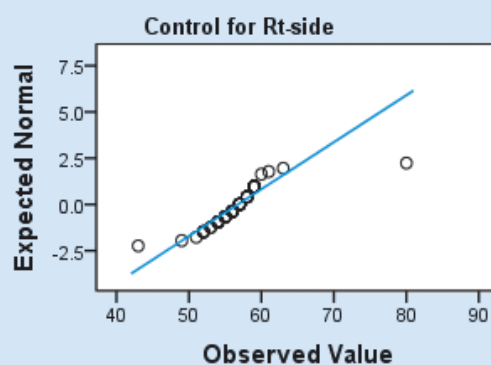
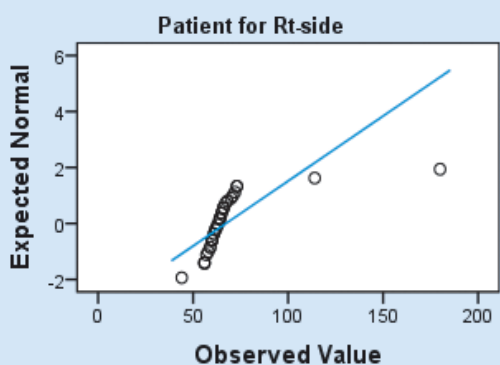
Tablica 3. Usporedba pacijenata s KS-om i kontrolne skupine na lijevoj strani
Table 3 Comparison of KS patients and controls of the left side

		N	Srednji rang • Mean Rank	Zbroj rangova • Sum of Ranks	Mann-Whitney	P-value
D • Rt	Pacijent • Patient	37	87.20	3226.50	362.500	0.000
	Kontrola • Control	78	44.15	3443.50		
	Ukupno • Total	115				
L • Lt	Pacijent • Patient	37	89.86	3325.00	264.00	0.000
	Kontrola • Control	78	42.88	3345.00		
	Ukupno • Total	115				



Slika 2. Usporedba pacijenata i kontrolne skupine za desnu i lijevu stranu

Figure 2 Comparison of patient and control of right and left sides



Slika 3. Q-Q grafikon desne i lijeve strane kod pacijenata i kontrolne skupine

Figure 3 Q-Q plot of right and left sides of patient and control

jenata s KS-om interval bio veći ($60,14^{\circ} - 74,51^{\circ}$) negoli za kontrolnu skupinu ($55,86^{\circ} - 57,63^{\circ}$), te na lijevoj strani (pacijenti s KS-om $60,64^{\circ} - 72,11^{\circ}$; kontrolna skupina $55,96^{\circ} - 57,42^{\circ}$). Minimalna vrijednost erupcijskog kuta kod pacijenata s KS-om iznosila je 44° na desnoj i 42° na lijevoj strani, a maksimalna vrijednost bila je 180° na desnoj i 162° na lijevoj strani. Minimalna vrijednost erupcijskoga kuta u kontrolnoj skupini iznosila je 43° na desnoj i 44° na lijevoj strani. Maksimalna vrijednost bila je 80° na desnoj i 76° na lijevoj strani, tablica 1., slika 3.

Srednja vrijednost erupcijskoga kuta maksilarnog očnjaka kod pacijenata s KS-om iznosila je $67,32^{\circ}$ na desnoj i $66,38^{\circ}$

val was constructed for mean of each group, the right side of patient group had a wider range of about ($60.14^{\circ}-74.51^{\circ}$) compared with the control group in which it amounted to ($55.86^{\circ}-57.63^{\circ}$), while the left side of the patient group was of ($60.64^{\circ}-72.11^{\circ}$) and the control group was of about ($55.96^{\circ}-57.42^{\circ}$). The minimum value of the eruption angle in KS patients was 44° on the right and 42° on the left side, and the maximum value was 180° on the right side and 162° on the left side. The minimum value of the eruption angle in the control group was 43° on the right side and 44° on the left. The maximum value was 80° on the right side and 76° on the left side, Table 1, Figure 3.

na lijevoj strani, bez statistički značajne razlike (tablica 2.). U kontrolnoj skupini je erupcijski kut na desnoj strani bio 56,74°, a na lijevoj strani 56,69°, bez statistički značajne razlike (tablica 3.). Vrijednosti standardnih devijacija razlikovale su se u skupinama, s mnogo većom vrijednošću u skupini pacijenata s KS-om (21,551) negoli u kontrolnoj (3,939) na desnoj strani, te nešto drukčijim rezultatima na lijevoj strani. To znači da u skupini s KS-om erupcijski kut nije bio homogen s obje strane, a u kontrolnoj skupini kutovi su bili vrlo slični i lijevo i desno. Iz tablice 2. vidi se da je postojala statistički značajna razlika između ovih dviju skupina na desnoj strani ($P < 0,01$). Tablica 3. pokazuje statistički značajnu razliku rezultata između ovih dviju skupina na lijevoj strani ($P < 0,01$).

Rasprava

U ovom istraživanju preispitivala se pretpostavka da se erupcijski kut PDC-a kod pacijenata s KS-om razlikuje u usporedbi s erupcijskim kutom u kontrolnoj skupini. Naši rezultati pokazali su za 10,58° veću vrijednost erupcijskoga kuta PDC-a u slučaju pacijenata s KS-om u usporedbi s vrijednošću erupcijskoga kuta kod muškaraca u kontrolnoj skupini. Zabilježena su različita dentoskeletalna obilježja kod pacijenata KS-om, no prema autorovim spoznajama, ovo je prvi rad koji istražuje erupcijski kut PDC-a kod ovog poremećaja.

U ranijim istraživanjima (4–9) isticala se razlika u veličini i obliku tvrdog nepca pacijenata s kariotipom 47,XXY. Rezultati su pokazali znatno povećanu duljinu maksilarne baze, plitko tvrdo nepce i značajno veću maksilarnu intermolaru širinu. Mnoga istraživanja provedena na prigodnom uzorku dokazala su jasnu povezanost između PDC-a i dentalnih anomalija ili kongenitalne ageneze; njihovi rezultati bili su različiti i upozorili su na genetsku komponentu (23, 24, 27) i okolišne čimbenike (25, 27).

U literaturi postoje mnogobrojna istraživanja s kontrolnim zaključcima o raspoloživom prostoru u zubnom luku i njegovu utjecaju na PDC. Langberg i Peck (29) analizirali su širinu maksilarnog zubnog luka kod ispitanika s palatinalno impaktiranim očnjacima. Nisu pronađene značajne razlike u interpremolarim i intermolarim širinama ni kod pacijenata s PDC-om ni u kontrolnoj skupini. Takvi dokazi odbacuju ranije zaključke da je nedostatak maksilarne transverzalne širine luka čimbenik koji pridonosi genezi palatinalno impaktiranih očnjaka. Anić-Milosević i suradnici (28) istražili su dentalne i okluzijske karakteristike povezane s PDC-om. Zaključili su da nije bilo statistički značajne razlike u odnosu na gornju transverzalnu dimenziju, maksilarnu meziodistalnu širinu ili palatinalnu visinu među spolovima. Uzimajući u obzir ove nalaze, nema dvojbe da dodatni X-kromosom kontrolira i utječe na gene odgovorne za veličinu i položaj očnjaka, kao i na gene odgovorne za rast kostiju maksile, što rezultira palatinalnim pomakom očnjaka/impakcijom. Nadalje, povezujući učinak genetskih čimbenika na opći epigenetski čimbenik (spolni i hormoni rasta) postava-

The mean value of the eruption angle of the maxillary canine in KS was 67.32° on the right side and 66.38° on the left side with no statistical difference (Table 2). In the control group, the eruption angle on the right side was 56.74° and it was 56.69° on the left side with no significant statistical differences between them (Table 3). Although the standard deviation values differ in groups, they were higher in the patient group (21.551) than in the control group (3.939) on the right side. Slightly different results were found on the left side, which means that the KS patient group was not homogeneous regarding the eruption angle on the left side, while values in the control group were alike on both sides. From Table 2 it can be seen that there was a significant difference between those two groups on the right side (P -value < 0.01). Table 3 shows a significant difference in results between the two groups, particularly those related to the left side (P -value < 0.01).

Discussion

The current study tested the hypothesis that the eruption angle of PDC in KS patients differs from the eruption angle in casual patients. Our results showed increased eruption angle values of PDC in KS patients (by 10.58°) compared with eruption angle values in the casual male control group. Various dentoskeletal features in KS patients have been reported, but, to the authors' knowledge, this is the first study analyzing the eruption angle of PDC in patients with Klinefelter syndrome.

Previous studies (4-9), have reported characteristic differences of the hard palate size and shape in patients with karyotype 47, XXY chromosome. The results of those studies pointed to significantly increased length of the maxillary base, shallow hard palate, and significantly increased maxillary intermolar width. A large number of studies were focused on casual patients in order to demonstrate a clear association between the PDC of the maxillary canine and anomalous or congenital tooth absence. The results of those studies were different and they pointed to genetic components (23, 24, 27) and environmental factors (25, 27).

In the literature, there are numerous studies with controversial conclusions regarding the available space in dental arches and its contribution to the PDC. Langberg and Peck (29) investigated into the maxillary dental arch width in subjects with palatally displaced canines. They did not find any significant differences in interpremolar and intermolar widths either in PDC patients or controls. They have provided evidence for refuting previous conclusions which stated that deficiency in maxillary transverse arch width is an associated contributing factor in genesis of the anomaly of palatally displaced canines. Anić-Milosevic *et al.* (28) investigated into dental and occlusal features associated with PDC in casual age group patients and their contribution to the etiology of PDC. They concluded that there was no statistically significant difference between the groups with regard to maxillary transverse dimensions, maxillary mesiodistal widths, or palatal height for either gender. Thus, considering all these observations, there is no doubt that the extra X chromosome controls and influences the genes responsible for canine size and

je očit utjecaj dodatnoga kromosoma na rast kraniofacijalnih struktura u razdoblju spolnog sazrijevanja.

Kod muškaraca s KS-om utvrđen je prekomjeran rast zuba; imaju taurodontizam i radikulomegaliju. Potvrđeno je da se povećana duljina gornjeg očnjaka očituje u dobi od 8 do 14 godina (43, 44), a s obzirom na erupcijski slijed (45) i proces preoblikovanja tvrdog nepca i maksile koji se događaju istodobno. Međusobna povezanost PDC-a i palatinalnog rasta kosti povezana je s interferencijom dodanoga X-kromosoma. N. Suda i K. Moriyama (46) raspravljali su o svim anomalijama korijena u preglednom radu i naveli da su one povezane sa sindromima, a ne pojavljuju se kao samostalna stanja. Bez obzira na to, oni ne opovrgavaju prisutnost specifičnih molekula koje imaju ekspresiju tijekom procesa formiranja korijena. Kanavakis i suradnici (33) analizirali su angulaciju krune prema korijenu lateralnih sjekutića u blizini impaktiranih očnjaka u dvije skupine – u jednoj s impakcijom i jednoj bez impakcije. Otkrili su značajnu razliku u angulaciji krune prema korijenu između skupina. Korijen lateralnih sjekutića koji su se nalazili u neposrednoj blizini impaktiranih očnjaka bio je nagnut više mezijalno u odnosu na bočne sjekutiće pokraj neimpaktiranih očnjaka. Naši rezultati potvrđuju ovaj nalaz uzimajući u obzir vrijeme erupcije, palatalni nagib korijena i završetak razvoja bočnih sjekutića koji se pojavljuju istodobno s mehanizmima stvaranja kosti tijekom vrhunca rasta.

Rendgenske snimke potrebne su za pregledavanje impaktiranih očnjaka u tri dimenzije (vertikalna, meziodistalna i bukopalatalna) kako bi se utvrdio odnos prema sredini i susjednim zubima i procijenila prisutnost resorpcije (41). Ako nije dostupna suvremena tehnologija ili softversko rješenje, obični ortopantomogram u kombinaciji s linearnim i kutnim mjerenjima još uvijek je korisna i točna metoda. Go-Go metoda omogućuje dvodimenzionalnu procjenu PDC-a i prostornih odnosa u odnosu na susjedne strukture. Položaj i mjerenje PDC-a metodom Go-Go na ortopantomogramu pomaže u utvrđivanju točnog nagiba PDC-a i daje informacije o susjednim strukturama. Go-Go metoda je jednostavna, jeftina i konstruktivna te se može primijeniti u svim stomatološkim klinikama. Povećana vrijednost erupcijskog kuta može u nekim situacijama pomoći kliničarima i dati im smjernice za procjenu pacijenta i utvrđivanje eventualnih poteškoća.

Ograničenje ovog istraživanja povezano je s korištenjem ortopantomograma kako bi se odredio erupcijski kut PDC-a i nemogućnost uspoređivanja s drugim metodama ili sofisticiranijim tehnologijama. Dosadašnja istraživanja sugeriraju da mjerenja na panoramskim snimkama imaju tendenciju precjenjivanja meziodistalne angulacije korijena u usporedbi s trodimenzionalnim slikama (41). Osim toga, postoji inherentna pogreška u korištenju dvodimenzionalne slike kako bi se prikazale trodimenzionalne strukture jer bukodistalna angulacija može utjecati na meziodistalne mjere na panoramskoj snimci (40). Mogući dobni dimorfizam erupcijskog kuta PDC-a također je mogao utjecati na rezultate ovog istraživanja. Unatoč tim ograničenjima, dobiveni rezultati još uvijek imaju značajnu kliničku vrijednost, posebno zato što je ortopantomogram i dalje najčešće korištena rendgenska snimka u dentalnoj medicini. Rano otkrivanje poremećaja erupcije oč-

position as well as it does over the genes responsible for bone growth of the maxilla resulting in palatal displacement of canine / impaction. Furthermore, by relating the effect of genetic factor to general epigenetic factor (sex and growth hormone), control of an extra chromosome over the growth of the craniofacial structures at the time of sexual maturation becomes obvious.

Men with KS have excessive tooth growth. They have taurodontism and radiculomegaly. It has been confirmed that the root elongation of maxillary canine becomes evident between the ages of 8 to 14 (43, 44), and with regard to the eruption sequence (45), and with regard to the remodeling process of the hard palate and maxilla that take place simultaneously. The interrelation between PDC and palatal bone growth shows interference by presence of genes on the extra X chromosome. Suda N and Moriyama K (46), have discussed all root abnormalities in a review article and they postulated that root abnormality is seen syndromically but not solely as a dental condition. However, they have not denied the presence of specific molecules that are only expressed during the process of root formations. Also, they have not denied involvement of tooth development regulators. Kanavakis *et al.* (33) investigated into the crown-root angulation of lateral incisors adjacent to palatally impacted canines in two groups: one with impacted and one without canine impaction. They found significant differences in crown-to-root angulation between the groups. The root of lateral incisors adjacent to palatally impacted canines was angulated more mesially compared to adjacent lateral incisors in the 'not impacted' canine group. Our results confirm this finding if we take into consideration the time of eruption sequence, palatal root inclination and completion of laterals that occur concomitantly with bone formation mechanisms during growth spurt timing.

Radiographs are required to view impacted canines in three dimensions (vertical, mesio-distal and buccopalatal), to view the relationship to the midline and adjacent teeth and to evaluate any resorption (41). If an advanced apparatus or software solution cannot be acquired, panoramic radiographs combined with linear and angular measurements are still valuable and accurate. The Go-Go method allows a two dimensional evaluation of PDC and spatial relationships relative to adjacent structures. Localization and measurements of PDC by the Go-Go method on panoramic radiographs contributes to accurate exhibition of inclinations of the PDCs and provides information regarding the adjacent structures. The Go-Go method is a simple, cheap, and constructive method that can be performed in ordinary dental clinics. An increased value of the canine eruption angle may help clinicians in some situations and give guidelines for the assessment of the patient and to estimate the treatment difficulty.

A limitation of this study is associated with the use of panoramic radiographs to determine eruption angle of PDC and missing comparability with other methods on casual patient or with more sophisticated technology. Previous studies have suggested that measurements on panoramic radiographs tend to overestimate the mesiodistal root angulation when compared to a three-dimensional image (41). In addition, there is an inherent error in using a two dimensional image

njaka kod muškaraca moglo bi upozoriti na prisutnost drugih povezanih dentoskeletnih anomalija. U nekim slučajevima pacijenta treba uputiti na genetske pretrage kako bi im se odredili genotip i kariotip.

U istraživanju koje su Yu i suradnici (34) proveli na prigodnom uzorku, prosječna vrijednost mezijalne inklinacije impaktiranih očnjaka u odnosu na okluzalnu ravninu iznosila je između 53,8° i 68,5°. Kod muškaraca s KS-om utvrđena je statistički značajna razlika u vrijednostima erupcijskoga kuta. Uspoređujući naše nalaze s rezultatima drugih istraživanja provedenih na pacijentima s PDC-om, čini se da je povećana mezioangularna inklinacija PDC-a posljedica rasta uzrokovanog dodatnim X-kromosomom. Geni koji utječu na dentalni rast kontroliraju i druge procese rasta i razvoja. Stoga se čini da dodatni X-kromosom u slučaju KS-a utječe na položaj maksilarnog očnjaka i njegov erupcijski put u usporedbi sa zdravim muškarcima.

Zaključak

Korištenjem Go-Go metode kliničari mogu jednostavno i brzo izmjeriti i potvrditi prelazi li erupcijski kut vrijednost od 56,74°. Doktori dentalne medicine i ortodonti trebaju imati na umu KS pri pregledu muškaraca s erupcijskim poremećajem maksilarnih očnjaka. Pravodobno prepoznavanje PDC-a može pomoći u ranoj identifikaciji Klinefelterova sindroma s odgovarajućim anticipativnim mjerama. Genetski mehanizmi na kojima se temelji PDC trebaju se dalje razjasniti s obzirom na fenotip.

Sukob interesa

Nije bilo sukoba interesa.

to depict three-dimensional structures since the bucco-distal tooth angulations might influence mesio-distal measurements on panoramic radiographs (40). Possible age dimorphism in PDC eruption angle could have also affected the results of this investigation. Despite these limitations, there is substantial clinical value to the findings of this study, especially because the panoramic radiograph is still most commonly used radiograph in dentistry. Early detection of disturbed canine eruption in males might alert to the presence of other associated dentoskeletal feature(s). In some instances, the patient should be referred for genetic examinations, determining genotype and karyotype.

In a study by Yu *et al.* (34), which was carried out on casual patients, the mesial inclinations angle values of the impacted canines to the occlusal plane were reported to be between 53.8° and 68.5° on average. Significant statistical differences in eruption angle values were observed in KS men. By comparing our findings with the results of other studies performed on casual patients with PDC, the increased mesioangular inclination of PDC seems to have arisen from dental growth genes within the extra X chromosome. The gene(s) influencing dental growth have also control over other events in the process of growth and development. Therefore, the additional X chromosome in KS patients appears to have an influence on the maxillary canine position and its eruption pathway compared with unaffected males.

Conclusions

By using the Go-Go method, dental clinicians can easily and quickly measure and confirm the fact that the eruption angle value exceeds 56.74°. Dental practitioners and orthodontists should be aware of the Klinefelter syndrome when examining males for eruption disturbances of maxillary canines. Early recognition of PDC can lead to early identification and anticipatory guidance that is extremely helpful in treatment of this syndrome. Genetic mechanisms underlying PDC need to be further elucidated with regard to the phenotype of PDC.

Conflict of Interest

None declared

Abstract

Objective: To investigate the eruption angle of maxillary canine in patients with Klinefelter syndrome (KS) in which high prevalence of palatally displaced canine anomaly (PDC) has been found by clinical assessment. **Subjects and Methods:** The sample consisted of 37 KS males aged 20-34 years (mean 27 years) and the control group which consisted of 78 healthy males aged 20-27 years (mean 23 years). A pioneer method was used to measure the eruption angle. It was based on determining the topographic construction of mandibular gonion line called GO-GO method on panoramic radiograph. **Results:** The mean of eruption angle was increased for 10.58° in the right side and 9.69° in left side in patients with KS compared to those in the control group. The difference of mesioangular inclination of palatally displaced canines in Klinefelter patients was statistically significant ($p < 0.01$). When eruption angle in the control group was compared to Klinefelter patients, the statistical difference was confirmed for respective sides ($P < 0.01$ for both). **Conclusions:** The difference between eruption angle values in KS patients as well as in those belonging to the control group seemed to identify a developmental disturbance, thus confirming the fact that an extra X chromosome has an influence. The GO-GO method might be used for males when it is difficult to define occlusal planes, or for comparison. If this method is used, the eruption angular values should not exceed 56.74°.

Received: May 9, 2017

Accepted: November 6, 2017

Address for correspondence

Associate Professor Ahmed Abulwefa, PhD
Tripoli University
Faculty of Dental Medicine and Oral Surgery
Department of Orthodontic-Pedodontic-Preventive Dentistry
Tripoli, Libya
abulwefa2009@yahoo.com

Key words

Klinefelter Syndrome; Tooth Eruption, Ectopic; Palate, Hard; Canine; Panoramic Radiography; Sex Chromosome Disorders

References

- Brown T, Alvesalo L, Townsend GC. Craniofacial patterning in Klinefelter (47 XXY) adults. *Eur J Orthod.* 1993 Jun;15(3):185-94.
- Boiesen A, Gravholt CH. Klinefelter syndrome in clinical practice. *Nat Clin Pract Urol.* 2007 Apr;4(4):192-204.
- Davis SM, Cox-Martin M, Bardsley M, Kowal K, Zeitler PS, Ross JL. Effects of Oxandrolone on cardiometabolic health in boys with Klinefelter syndrome: A randomized controlled trial. *J Clin Endocrinol Metab.* 2017 Jan 1;102(1):176-184.
- Brkić H, Kaić Z, Poje Z, Singer Z. Shape of the craniofacial complex in patients with Klinefelter syndrome. *Angle Orthod.* 1994;64(5):371-6.
- Babić M, Mičić N, Jakšić N, Mičić S. An extra X chromosome effect on craniofacial morphogenesis in men. *Eur J Orthod.* 1991 Aug;13(4):329-32.
- Poje Z, Škrinjaric I, Kaić Z, J Štefanac-Papić. Prevalence of malocclusion in patients with gonadal dysgenesis. *Coll Antropol.* 1996; 1:201-206.
- Laine T, Alvesalo L. Palatal and alveolar arch dimensions in 47, XXY (Klinefelter syndrome) men. *Hum Biol.* 1993 Feb;65(1):131-8.
- Poje Z, Kaić Z, Škrinjaric I, Dumić M. Gonadal dysgenesis and palatal features. *Am J Hum Genet.* 1991;49:1466.
- Kaić Z, Brkić H, Poje Z, Njemirovski V, Dorn V. Hard palatal size and shape in 47, XXY males. *J Coll Antropol.* 1996; 20:87-91.
- Šćepan I, Babić M, Glišić B. Mesiodistal dimension of permanent teeth in men with Klinefelter's syndrome. *Eur J Orthod.* 1993 Jun;15(3):195-7.
- Lahdesmäki R, Alvesalo L. Root lengths in 47,XXY males' permanent teeth. *J Dent Res.* 2004 Oct;83(10):771-5.
- Alvesalo L. Human sex chromosomes in oral and craniofacial growth. *Arch Oral Biol.* 2009 Dec;54 Suppl 1:S18-24.
- Krishnamoorthy S, Gopikrishna V. Endodontic management of a hypertaurodontic tooth associated with 48, XXYY syndrome: A review and case report. *J Conserv Dent.* 2015 May-Jun;18(3):265-8.
- Hata S, Maruyama Y, Fujita Y, Mayangi H. The dentofacial manifestations of XXXXY syndrome: a case report. *Int J Paediatr Dent.* 2001 Mar;11(2):138-42.
- Parhiz A. A rare case of multiple impacted teeth in a Klinefelter patient. *J Craniomax Res.* 2014;1: 66-68.
- Kaić Z, Abulwefa A, Štefanac-Papić J, Brkić H. Prevalence of the palatally displaced canine in 47, XXY males. *J Dent Res.* 1998; 77: 3057.
- Kaić Z, Abulwefa A, Poje Z, Štefanac-Papić J, Brkić H. Dentofacial anomalies in XXY males (Klinefelter syndrome). *J Dent Res.* 2001;80:1224.
- Alvesalo L, Laine T. Occlusion in 47, XXY (Klinefelter syndrome) men. *Am J Phys Anthropol.* 1992 Feb;87(2):161-5.
- Peck S, Peck L, Kataja M. The palatally displaced canine as a dental anomaly of genetic origin. *Angle Orthod.* 1994;64(4):249-56.
- Hitchen AD. The impacted maxillary canine. *Br Dent J.* 1956; 100:1-14.
- Jacoby H. The etiology of maxillary canine impactions. *Am J Orthod.* 1983 Aug;84(2):125-32.
- Fournier A, Turcotte JY, Bernard C. Orthodontic considerations in the treatment of maxillary impacted canines. *Am J Orthod.* 1982 Mar;81(3):236-9.
- Sacerdoti R, Baccetti T. Dentoskeletal features associated with unilateral or bilateral palatal displacement of maxillary canines. *Angle Orthod.* 2004 Dec;74(6):725-32.
- Zilberman Y, Cohen B, Becker A. Familial trends in palatal canines, anomalous lateral incisors and related phenomena. *Eur J Orthod.* 1990 May;12(2):135-9.
- Peck S, Peck L, Kataja M. Concomitant occurrence of canine malposition and tooth agenesis: evidence of orofacial genetic fields. *Am J Orthod Dentofacial Orthop.* 2002 Dec;122(6):657-60.
- Jang E, Lee K, An S, Song J, Ra J. Retrospective study of association between displacement of maxillary canine and tooth Agensis. *J Clin Pediatr Dent.* 2015 Fall;39(5):488-92.
- Becker A, Sharabi S, Chaushu S. Tooth size variation in dentitions with palatal canine displacement. *Eur J Orthod.* 2002 Jun;24(3):313-8.
- Anic-Milosevic S, Varga S, Mestrovic S, Lapter-Varga M, Slaj M. Dental and occlusal features in patients with palatally displaced maxillary canines. *Eur J Orthod.* 2009 Aug;31(4):367-73.
- Langberg BJ, Peck S. Adequacy of maxillary dental arch width in patients with palatally displaced canines. *Am J Orthod Dentofacial Orthop.* 2000 Aug;118(2):220-3.
- Ericson S, Kuroj J. Early treatment of palatally erupting maxillary canines by extraction of the primary canines. *Eur J Orthod.* 1988 Nov;10(4):283-95.
- Ericson S, Kuroj J. Radiographic examination of ectopically erupting maxillary canines. *Am J Orthod Dentofacial Orthop.* 1987 Jun;91(6):483-92.
- Ericson S, Kuroj J. Resorption of maxillary lateral incisors caused by ectopic eruption of the canines. *Am J Orthod Dentofacial Orthop.* 1988 Dec;94(6):503-13.
- Kanavakis G, Curran KM, Wiseman KC, Barone NP, Finkelman MD, Srinivasan S, et al. Evaluation of crown-root angulation of lateral incisors adjacent to palatally impacted canines. *Prog Orthod.* 2015 Feb 26;16:4.
- Yu JN, Gu YG, Zhao CY, Liu K, Ko SC, Li H, Pan CQ, Wang L. Three dimensional localization and assessment of maxillary palatal impacted canines with cone-beam computed tomography. *Shang Kou Qiang Yi Xue.* 2015; 24:65-70.
- Cernochova P, Izakovicova-Holla L. Dentoskeletal characteristics in patients with palatally and buccally displaced maxillary permanent canines. *Eur J Orthod.* 2012 Dec;34(6):754-61.
- Novak HM, Baccetti T, Sigler LM, McNamara JA Jr. A controlled study on diagnostic and prognostic measurements of palatally displaced canines on lateral cephalograms. *Prog Orthod.* 2012 May;13(1):42-8.
- Algerban A, Storms AS, Voet M, Fieuws S, Willems G. Early prediction of maxillary canine impaction. *Dentomaxillofac Radiol.* 2016;45(3):20150232.
- Naoumova J, Kjellberg H, Palm R. Cone-beam computed tomography for assessment of palatal displaced canine position: a methodological study. *Angle Orthod.* 2014 May;84(3):459-66.
- Shah S, Uppal SK, Mittal RK, Garg R, Saggar K, Dhawan R. Diagnostic tools in maxillofacial fractures: Is there really a need of three-dimensional computed tomography? *Indian J Plast Surg.* 2016 May-Aug;49(2):225-233.
- Bouwens DG, Cevidanes L, Ludlow JB, Phillips C. Comparison of mesiodistal root angulation with posttreatment panoramic radiographs and cone-beam computed tomography. *Am J Orthod Dentofacial Orthop.* 2011 Jan;139(1):126-32.
- Stivaros N, Mandall NA. Radiographic factors affecting the management of impacted upper permanent canines. *J Orthod.* 2000 Jun;27(2):169-73.
- Čelebić A, Brkić H, Kaić Z, Vojvodić D, Poje Z, Singer Z. Occlusal plane orientation in Klinefelter syndrome (47,XXYmales). *J Oral Rehabil.* 1997 Dec;24(12):942-6.
- Lähdesmäki R, Alvesalo L. Root lengths in the permanent teeth of Klinefelter (47, XXY) men. *Arch Oral Biol.* 2007 Sep;52(9):822-7.
- Saiar M, Rebellato J, Sheats RD. Palatal displacement of canines and maxillary skeletal width. *Am J Orthod Dentofacial Orthop.* 2006 Apr;129(4):511-9.
- Rawson KG, Hofelich R, Welch DB, Stoeckel DC. Eruption sequence of the permanent maxillary canine: a radiographic review. *Gen Dent.* 2014 Jul-Aug;62(4):e9-e11.
- Suda N. and Moriyama K. The mechanisms controlling root morphogenesis in mammalian molars. Human diseases associated with abnormal tooth roots. *J Oral Biosci.* 2009; 51:199-204.