

Ema Vrbanović<sup>1\*</sup>, Iva Z. Alajbeg<sup>2</sup>

## Mlada pacijentica s osteoartritisom temporomandibularnog zgloba: prikaz slučaja

### A Young Patient with Temporomandibular Joint Osteoarthritis: Case Report

<sup>1</sup> Studentica poslijediplomskog doktorskog studija na Stomatološkom fakultetu Sveučilišta u Zagrebu  
*PhD student, School of Dental Medicine, University of Zagreb, Croatia*

<sup>2</sup> Zavod za mobilnu protetiku Stomatološkog fakulteta Sveučilišta u Zagrebu  
*Department of Prosthodontics, School of Dental Medicine, University of Zagreb, Croatia*

#### Sažetak

U ovom radu opisan je slučaj mlade pacijentice koja je zatražila pomoć zbog bolova u desnom temporomandibularnom zglobo (TMZ) koji su se pojačavali tijekom žvakanja. Kliničkim pregledom ustanovljeno je da pri kretnji otvaranja postoji ograničenje kretnje i neispravljena devijacija prema bolnoj strani. Palpacijom lateralnoga pola desnog kondila nađene su krepitacije, a asistirano otvaranje usta izazvalo je kod pacijentice pojavu poznate, već doživljene boli. Dijagnoza osteoartritis TMZ-a (RDC/TMD kriteriji, Os I, Skupina III) potvrđena je snimanjem čeljusnih zglobova CBCT-om. U izboru terapijskih oblika TMP-a ne postoji *zlatni standard*, ali liječenje se mora temeljiti na preciznim indikacijama vezanima za prisutnost boli, ograničenje funkcije donje čeljusti te znakove degenerativnih promjena TMZ-a. Pritom se preferiraju konzervativni, reverzibilni terapijski postupci kojima je svrha poboljšati funkciju cjelokupnoga žvačnog sustava. U ovom slučaju liječenje se sastojalo od kombinacije fizikalne terapije i stabilizacijske udlage koje su za cilj imale smanjenje boli i vraćanje normalne funkcije čeljusti. Na kontroli nakon šest mjeseci tegobe su gotovo potpuno nestale, a tri godine poslije pacijentica i dalje nema većih subjektivnih tegoba. U opisanom slučaju neinvazivna je terapija bila dostatna da dovede, inače cikličku prirodu osteoartritis, u mirno stanje i tako se zadrži godinama.

**Zaprimljen:** 11. prosinca 2016.  
**Prihvaćen:** 21. srpnja 2017.

#### Adresa za dopisivanje

Ema Vrbanović, dr. med. dent.  
Franje Puškarića 32, 10 250 Lučko  
tel: +385 1989377644  
evrbanovic@sfg.hr

#### Ključne riječi

poremećaji čeljusnog zgloba; osteoartritis; okluzijska udlaga; fizikalna terapija

#### Uvod

Osteoartritis (OA) je degenerativna bolest zglobova koju obilježava degeneracija hrskavice, skleroza subhondralne kosti i formiranje osteofita. Kao i sve ostale zglobove u tijelu, osteoartritis može zahvatiti i temporomandibularni zglob, pri čemu destruktivne koštane promjene uzrokuju bol i/ili disfunkciju zgloba pri kretnji donje čeljusti. Etiologija i patofiziologija OA-e je kompleksna, a uloga u nastanku često se pripisuje različitim lokalnim i sistemskim čimbenicima koji u nastanku patološkog stanja uglavnom djeluju sinergijski, pa zato OA-u možemo opisati kao multifaktorijsku bolest (1). Ipak, u literaturi se najčešće kao uzrok nastanka spominje poremećaj ravnoteže između dinamičkih procesa (opterećenje zgloba pri funkcijskim i parafunkcijskim kretanjima čeljusti) i sposobnosti TMZ-a da ih tolerira s pomoću prilagodljivosti svoje specifične građe, funkcijske pregradnje i reparacije tkiva (2). Sam poremećaj ravnoteže između tih procesa i mogućnosti zgloba da se prilagodi može biti posljedica različitih stresora čije djelovanje počinje na molekularnoj razini, a akumulacija promjena na molekularnim razinama rezultira makropromjenama koje se katkad očituju vidljivim poremećajima funkcije tijekom kliničkih pregleda (1).

#### Introduction

Osteoarthritis (OA) is a degenerative joint disease characterized by degeneration of cartilage, subchondral bone sclerosis and formation of osteophytes. Like all other joints in the body, osteoarthritis can affect the temporomandibular joint, where destructive bone changes cause pain and / or dysfunction of the joint during mandibular movements. The etiology and pathophysiology of OA are complex, and the role in the onset of OA is often attributed to a variety of local and systemic factors that generally act synergistically in the occurrence of a pathological condition. Therefore, OA is considered to be multifactorial disease (1). According to the current literature, the degenerative changes in the TMJ are believed to result from the imbalance between dynamic processes (joint loading during functional and parafunctional movements of the jaw) and ability of the TMJ to tolerate the same with the help of the flexibility of its specific structure, functional remodeling and tissue repair (2). Imbalance between dynamic processes and the ability of the joint to adapt can be caused by different stressors whose action begins at the molecular level. The accumulation of changes at the molecular level may result in macrochanges that some-

Dijagnostika OA-e počinje anamnezom, a nastavlja se kliničkim pregledom i korištenjem radioloških metoda. Pacijent s osteoartritisom često navodi unilateralnu bol zgloba i mekih tkiva oko njega koja se pogoršava pri krenji donje čeljusti, a nerijetko su prisutne i krepitacije. Kliničkim pregledom potrebno je ustanoviti svako odstupanje od normalne funkcije stomatognatog sustava. Ispitivanje se sastoji od pregleda mišića, zglobova i zuba te detekcije ograničenosti i smetnji pri funkcionalnim pokretima čeljusti. Posebno je važno zabilježiti koji od pokreta uzrokuju bol i pojavu zvukova klikanja ili drobljenja (krepitus) (3). Dijagnostički kriterij za istraživanje TMP-a (engl. Research Diagnostic Criteria for Temporomandibular Disorders – RDC/TMD), odnosno njegova novija, poboljšana verzija DC/TMD, omogućuje standardizaciju najčešćih oblika TMP-a povezanih s mišićima i zglobovima (4). Budući da klinički znakovi i simptomi nisu uvijek najjasniji pokazatelj degenerativnih promjena u zglobu, pravilna dijagnoza OA-e postavlja se na temelju kliničkog pregleda koji može biti praćen i radiološkim metodama. Kompjutorizirana tomografija (CT) i *cone-beam* CT (CBCT) omogućuju precizan prikaz koštanih struktura i tvrdih tkiva te su pouzdane metode za otkrivanje koštanih promjena. CBCT je relativno nova metoda koja omogućuje vizualizaciju tvrdih tkiva uz razmjerno nisku dozu zračenja. Magnetska rezonancija (MR) vrlo je važna u dijagnostici pomaka zglobne pločice (5). Konvencionalna radiološka dijagnostika, primjerice ortopantomogram, može prikazati uznapredovalu destrukciju koštanoga tkiva u obliku zaravnjenja, no nije dovoljno detaljna kad je riječ o analizi stupnja i uznapredovalosti OA-e. Glavne radiološke karakteristike za dijagnozu OA-e su osteofiti, erozije i subkortikalna pseudocista (6). Dijagnoza osteoartritisa još je izazov zbog slabe povezanosti između simptoma i radiološkog dokaza razorenosti zgloba (7).

Terapija OA-e može se podijeliti na neinvazivnu i invazivnu koja obuhvaća kiruršku terapiju i tzv. minimalno invazivne metode aplikacije različitih sredstava u zglob, bez obzira na nedostatak pravih znanstvenih dokaza o njihovoj djelotvornosti (1). Neinvazivna terapija uključuje edukaciju pacijenta, različite tehnike relaksacije, fizikalnu terapiju, primjenu različitih vrsta okluzijskih udlaga i ostale metode koje pomažu olakšati simptome. U neinvazivnu terapiju također možemo ubrojiti medikaciju i to najčešće nesteroidne antireumatičke koji dobro djeluju na bolove u mišićno-koštanom sustavu. Stabilizacijska udlaga najčešće je korištena metoda u terapiji temporomandibularnih poremećaja (TMP) (2). Privremena promjena položaja kondila i povećanje vertikalne dimenzije najvjerojatnije pridonose relaksaciji mišića i smanjenju bolova mišićnoga i zglobnog podrijetla. Unatoč nemogućnosti izravnog djelovanja na OA-u, stabilizacijska udlaga može pridonijeti redukciji utjecaja različitih rizičnih čimbenika na zglob (8–9).

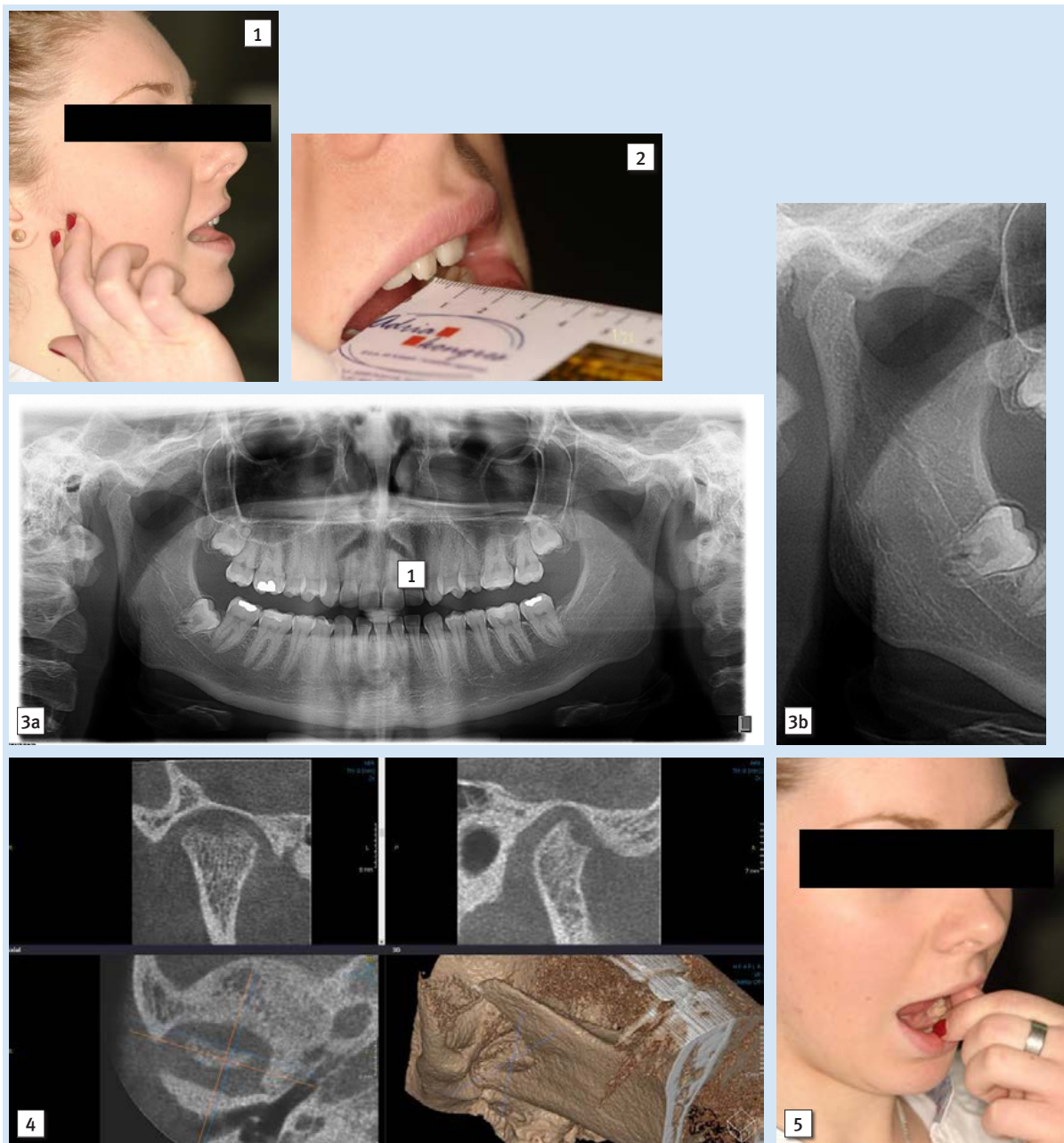
U minimalno invazivna terapijska sredstva ubrajaju se metode koje obuhvaćaju aplikaciju različitih sredstava u zglob od kojih se u literaturi spominju aplikacija kortikosteroida, lokalnih anestetika i plazme bogate čimbenicima rasta (PRGF) (10) te artrocenteza (uklanjanje upalnog eksudata) u kombinaciji s injekcijama hijaluronske kiseline. Invazivna tj. kirurška terapija ima malu ulogu u liječenju OA-e koja ne

times manifest as functional disorders during clinical examinations (1).

Diagnosis of OA includes medical history, clinical functional analysis, and radiological methods. Unilateral pain in the joint and soft tissue around it which increases during mandibular movements, as well as crepitus, may often be present. Clinical examination is necessary to determine any deviation from the normal function of masticatory system. Clinical evaluation includes the assessment of pain during the palpation of masticatory muscles, joint palpation, detection of limitations and interferences during functional jaw movements, as well as assessment of occlusion. It is very important to note which of the movements cause pain and the occurrence of clicking sounds or crepitus (3). Research Diagnostic Criteria for Temporomandibular Disorders RDC / TMD, or its newer, improved version DC / TMD, enables standardization of the most common forms of TMD associated with muscles and joints (4). Since the clinical signs and symptoms are not always the clearest indication of the presence of degenerative joint disease, correct diagnosis is mandatory by critical clinical evaluation supported by imaging. Computerized tomography (CT) and cone-beam CT (CBCT) allow accurate visualization of bone structures and hard tissues. CBCT is a promising new method to visualize hard-tissue changes with a relatively low radiation dose. Magnetic resonance imaging (MRI) is of great importance in the diagnosis of dislocation of the disc (5). Conventional radiographs, for instance a panoramic radiograph, can display advanced destruction of bone tissue in the form of flattening, however, is not sufficiently detailed method for evaluating the severity of OA. Imaging of an osteoarthritic joint typically shows osteophytes, erosion and subcortical pseudocyst (6). The diagnosis of osteoarthritis is still a challenge because of the weak association between severity of symptoms and radiographic evidence of destruction of the joint (7).

Treatment of TMJ OA can be divided into non-invasive treatment and invasive treatment that include surgery as well as application of various agents into the joint. Recently, we have witnessed the increasing popularity of invasive methods, regardless of scarce scientific evidence of their effectiveness (1). Non-invasive treatments include patient education about different relaxation techniques, physical therapy, interocclusal appliances, and other methods that help in alleviating symptoms. The most common and effective medications used for TMD management are NSAIDs, that have well pain-relieving properties. Stabilization splint is the treatment of choice for pain control in temporomandibular disorder (TMD) patients (2). The appliance changes the position of mandibular condyles and increases the vertical dimension, so these effects may lead to muscle relaxation and a reduction of pain of myofascial origin and TMJ arthralgia. Despite the impossibility of direct action on OA, stabilization splint can contribute to the reduction of the impact of various risk factors to the joint (8-9).

Minimally invasive procedures include methods that comprise application of corticosteroids, local anesthetics, plasma rich growth factors (PRGF) (10) into the joint, as well as arthrocentesis (removal of inflammatory exudate) in combination with hyaluronic acid injections. Invasive or surgical



**Slika 1.** Prikaz ograničenog raspona otvaranja usta te pokazivanje mjesta boli

**Figure 1** Patient is pointing the area of pain during limited mouth opening.

**Slika 2.** Protuzija od 6 mm

**Figure 2** The protrusion of 6 mm.

**Slika 3.** Ortopantomogram prikazuje zaravnjenje desnoga TMZ-a

**Figure 3a** Panoramic radiograph showing flattening of the right condyle.

**Slika 3. b** Povećan prikaz zgloba zahvaćenog osteoartritisom

**Figure 3b** Enlarged view of the joint affected by osteoarthritis.

**Slika 4.** Prikaz osteoartritičnih promjena čeljusnog zgloba na slici CBCT-a

**Figure 4** Osteoarthritic changes of the TMJ on CBCT.

**Slika 5.** Asistirano istezanje predloženo kao metoda terapije (pacijentica lagano isteže mišiće u smjeru otvaranja usta)

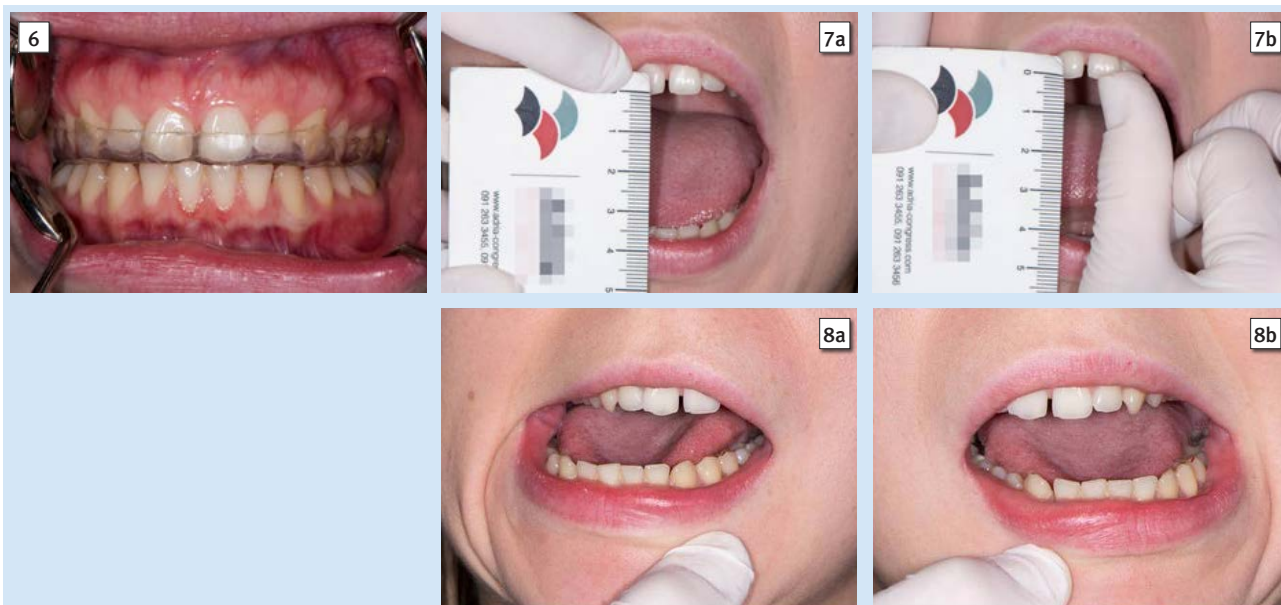**Figure 5** One of the treatment protocol considering self-administered exercises was assisted muscle stretching. Patient was instructed to apply gentle force to the elevator muscles with the fingers, in order to increase the amount of mouth opening.

reagira na manje invazivne terapije. Kao što je već prije istaknuto, pravih dokaza o djelotvornosti invazivnih metoda u liječenju jako je malo i stoga se njihova primjena, prema danas dostupnim podacima iz literature, ne preporučuje (12).

U velikom broju istraživanja pronađena je poveznica između pojavnosti i napredovanja osteoartritisa s dobi. Naime,

therapy plays a small but important role in the treatment of OA, particularly in patients who do not respond to less invasive therapies. The real proof of the effectiveness of invasive methods in the treatment of TMJ is very scarce (12).

A large number of studies have reported a relationship between the frequency and progression of osteoarthritis and



**Slika 6.** Stabilizacijskom udlagom postignut je fiziološki položaj koji je omogućio rasterećenje žvačnog sustava i pomogao u relaksaciji mišića djelujući kao deprogramator neuromuskularnog sustava, te su postignuti ravnomjerni kontakti zuba u položaju centrične relacije uz vertikalno podizanje okluzije za 2 mm

**Figure 6** Stabilization splint fabricated in physiological, centric relation position enabled relief of the masticatory system and helped in relaxation of muscles acting as deprogrammer of the neuromuscular system; uniform contacts of teeth in the centric relation position with increase of the vertical dimension of occlusion of 2 mm were present.

**Slika 7. a** Nakon 6 mjeseci neasistirano otvaranje usta iznosi 35 mm

**Figure 7a** After 6 months unassisted opening amounted to 35 mm.

**Slika 7. b** Nakon 6 mjeseci asistirano otvaranje usta iznosi 41 mm

**Figure 7b** After 6 months assisted opening amounted to 41 mm.

**Slika 8. a i b** Simetrični lateralni pomaci

**Figure 8a,b** Symmetrical lateral movements.

čeljusni je zglob u procesu starenja izložen mnogobrojnim biološkim promjenama. S godinama se povećava razina kalcija u disku i zato on postaje čvršći, ali i manje elastičan, pa je prema tome manje sposoban prilagoditi se većim opterećenjima (2, 13). Ipak, uznapredovali slučajevi osteoartritisa mogu se pronaći i u znatno mlađoj populaciji, pri čemu prednjače žene u dobi oko 35 godina, a znatan broj pacijenata u anamnezi navodi makrotraumu (2, 14, 15). Osim toga smatra se da ženski reproduktivni hormoni imaju posebnu ulogu u razvoju OA-e, osobito estrogen koji utječe na katabolizam fibrozno-hrskavičnog tkiva zgloba (16).

Svrha ovoga rada bila je osvrtno na ciljeve i mogućnosti konzervativne terapije OA-e. Također se željelo pokazati kako se uznapredovali slučajevi OA-e mogu pronaći i u mlađoj populaciji, što pridonosi opisu osteoartritisa kao etiološki i patofiziološki još uvijek ne sasvim jasnog stanja, čija je inicijacija kompleksna i ovisi o mnogobrojnim vanjskim i unutarnjim rizičnim čimbenicima. U radu je opisan slučaj mlade pacijentice u dobi od 21 godine sa znakovima i simptomima degenerativnih promjena TMZ-a.

### Prikaz bolesnika

Pacijentica u dobi od 21 godine upućena je u Zavod za mobilnu protetiku Stomatološkog fakulteta Sveučilišta u Zagrebu 2013. godine zbog bolova ispred i u području desnog TMZ-a koji su se pojačavali pri kretanju donje čeljusti. Iz anamneze se doznaje da je prije tri mjeseca sudjelovala u prometnoj nezgodi u kojoj je dobila jači udarac u glavu. Od tada su

age. This is because of the cumulative exposure of temporomandibular joint to a number of biological changes associated with aging. Aging increases the level of calcium in the articular disk and therefore it becomes stronger, but less elastic and less able to handle overload (2, 13). However, severe cases of osteoarthritis may be found in a much younger population, particularly women of around 35 years of age. A majority of those patients reported macrotrauma in the medical history (2, 14, 15). In addition, it is considered that the female reproductive hormones play a special role in the development of OA, especially estrogen, which influences the catabolism of cartilage-fibrous tissue of the joint (16).

The aim of this study was to review the goals and possibilities of conservative treatment of OA as well as to show how severe cases of OA can also be found in younger population. This contributes to the description of osteoarthritis as etiologically and pathophysiologically not quite clear condition which initiation is complex and depends on many external and internal risk factors. We report on a young, 21-year-old woman with signs and symptoms of degenerative changes of TMJ.

### Case report

The 21-year-old patient was referred to the Department of Prosthodontics, School of Dental medicine at the University of Zagreb in 2013 because of pain in front and in the right TMJ, which increased during mandibular movements. Medical history revealed that 3 months ago, the patient was involved in a traffic accident where she suffered a strong blow to the head.

počele tegobe u obliku otežanog i bolnog otvaranja usta, otežane lateralne kretnje donje čeljusti te otežana mastikacija.

#### Klinička dijagnostika

Palpacijom žvačnih mišića nisu bili provocirani bolovi, ali je palpacija lateralnog pola desnog kondila izazvala pojavu *poznate, već doživljene boli*. Palpatorno je uočen i krepitus desnoga čeljusnog zgloba. Kretnje otvaranja i protruzije također su izazivale pojavu *poznate boli*.

Evaluacijom raspona kretnji donje čeljusti ustanovljeno je ograničenje otvaranja – neasistirano otvaranje usta iznosilo je 22 mm interincizalno, a primjenom blage sile u smjeru otvaranja usta raspon otvaranja nije se uspio povećati više od 2 mm (slika 1.). Tijekom otvaranja usta bila je prisutna neispravljena devijacija udesno.

Bol u području desnog TMZ-a pojavila se pri lijevoj lateralnoj kretnji koja je iznosila 8 mm, a desna lateralna kretnja iznosila je 11 mm i to bez bolova. Iznos protruzije bio je 6 mm (slika 2.). Bol na analogno-vizualnoj ljestvici (VAS = 0 – 10) pacijentica je ocijenila kao VAS = 7. Pri lateralnim kretnjama detektiran je krepitus u području desnog kondila.

#### Zubni status

Kliničkim pregledom i analizom ortopantomograma ustanovljeno je da pacijentica ima sanirane zube bez protetičkih radova. Uočena je rastresitost zuba te pomak donje sredine ulijevo za oko 3 mm. Zubi 18, 28, 48 prisutni su i u nicanju, a zub 38 nedostaje. Vertikalni prijeklop i horizontalni pregriz iznosili su 4 mm.

#### Radiološka dijagnostika

Analizom ortopantomograma ustanovljeno je zaravnjenije desnoga kondila (slika 3.a i b). S obzirom na ograničene mogućnosti spomenute radiološke metode i nemogućnost prikaza stupnja i uznapredovalosti destrukcije kosti, dijagnoza osteoartritisa TMZ-a (RDC/TMD kriteriji, Os I, Skupina III) potvrđena je snimanjem čeljusnih zglobova CBCT-om. Na trodimenzionalnom prikazu desnoga zgloba (CBCT), pri zatvorenim i otvorenim ustima, vidljivo je da tijekom otvaranja kondil ne doseže do zglobne kvržice, što upućuje na hipomobilnost zgloba koja se klinički očitovala kao ograničen opseg kretnje pri otvaranju usta (slika 4.). To upućuje na moguću pomak zglobne pločice kao eventualni uzrok ograničenog otvaranja usta. No kako s pomoću CBCT tehnologije nije moguće procijeniti položaj zglobne pločice (17, 12), potvrđivanje dijagnoze pomaka zglobne pločice kao uzroka hipomobilnosti zgloba nije bilo moguće.

#### Terapija

Pacijentica je dobila upute za provođenje fizikalne terapije. Tretman se sastojao od ustaljenog protokola – vježbi pasivnog istezanja mišića (pacijent, gledajući se u zrcalo, vježba otvaranje usta po ravnoj putanji), te asistiranog istezanja (pacijent prstima lagano isteže mišiće te tako povećava otvaranje kod ograničenog otvaranja usta) (slika 5.). Nakon dva tjedna postignut je zadovoljavajući napredak u relaksaciji žvačne

Since then difficulties while opening and pain during the normal functional movements and mastication were present.

#### Clinical diagnostics

Palpation of the masticatory muscles did not provoke pain, but palpation of the lateral pole and provocation tests (opening and protrusive movements) produce report of “familiar pain”. Crepitus of the right TMJ was detected with palpation.

During clinical examination limitation in mouth opening was found, with unassisted opening of 22 mm. The application of mild force in the direction of the mouth opening failed to increase the opening of more than 2 mm (Figure 1). During mouth opening, uncorrected deviation to the right side was present.

Patient reported pain in the right TMJ during left lateral excursion. Left lateral movement was 8 mm, while the right lateral movement was 11 mm, and was carried out without pain. The amount of protrusion was 6 mm (Figure 2). Opening and protrusion provoked a report of “familiar pain.” Patient self-assessed the level of pain using visual-analog scale (VAS = 0-10) as VAS = 7. During lateral movements crepitus in the right TMJ was detected.

#### Dental status

Clinical examination and analysis of panoramic radiograph revealed that the patient’s teeth were treated previously and were without prosthodontic restorations. In the transversal plane there was a 3 mm displacement of the medial line. Interdental spacing was present. The teeth 18, 28, 48 were erupting, while the tooth 38 was missing. Vertical overbite and horizontal overjet amounted to 4 mm.

#### Radiological Diagnosis

Panoramic radiograph showed flattening of the right condyle (Figure 3 a and b). Since panoramic radiograph has limited display options of the degree and severity of bone destruction, the diagnosis of osteoarthritis of the TMJ (RDC / TMD criteria, Axis I, Group III) was confirmed by recording TMJ CBCT. On a three-dimensional view of the right joint (CBCT), taken in closed and open mouth positions, it was evident that during the opening the condyle did not reach to the articular eminence indicating joint hypomobility that was clinically manifested as limited range of mouth opening (Figure 4). This indicated the possibility of the disc dislocation. However, by using CBCT technology it is not possible to estimate the position of the articular disc (17, 12). Therefore it was not possible to confirm the disc dislocation as the cause of joint hypomobility.

#### Treatment

The patient was instructed to restrict the jaw movement to within painless limits. Instructions were provided for physical therapy to be employed during the day. The treatment protocol consisted of a self-administered exercises: passive muscle stretching (patient was encouraged to open on a straight opening pathway by looking in the mirror), and assisted muscle stretching (patient was instructed to apply gen-

muskulature te je pacijentici izrađena stabilizacijska udlaga u terapijskom položaju centrične relacije, uz podizanje vertikalne dimenzije okluzije za 2 mm te joj je preporučeno da udlagu nosi noću (slika 6.).

#### Naknadna skrb

Kontrolni pregledi obavljani su nakon mjesec dana, te nakon tri i šest mjeseci nošenja udlage. Na kontrolnom pregledu nakon šestomjesečnog redovitog nošenja udlage, postignuto je poboljšanje. Neasistirano otvaranje usta iznosilo je 35 mm, a asistirano 41 mm (slika 7. a i b). Lateralne kretnje bile su simetrične (slika 8. a i b). Povremena bol još se pojavljivala samo tijekom žvakanja tvrde hrane (VAS = 2). Palpacija lateralnog pola kondila nije bila bolna.

U studenome 2016. pacijentica je ponovno naručena na kontrolu. Iz anamneze se doznaje da se, uz redovito nošenje udlage noću, bolovi vrlo rijetko pojavljuju i to samo pri žvakanju guma za žvakanje. Ali ako neko vrijeme ne nosi udlagu, pojavljuju se glavobolje i otežano žvače tvrdu hranu. Kliničkim pregledom pronađena je blaga defleksija tijekom otvaranja, a u desnom zglobu još se mogu osjetiti krepitacije.

#### Rasprava

Osteoarthritis temporomandibularnog zgloba obuhvaća različite varijacije u patofiziologiji, epidemiologiji, progresiji poremećaja, te znakovima i simptomima. Važno je spomenuti da od početka pojave simptoma i znakova, pa do klinički značajnih destrukcija zgloba mogu proći godine, ali može napredovati i vrlo brzo (2). Upravo zbog različitog spektra pojavnosti i očitovanja, OA ostaje stanje čiji su dijagnostika i terapija predmet rasprava i istraživanja. Metode koje se često spominju, a obuhvaćaju aplikaciju kortikosteroida, hijaluronske kiseline ili PRGF-a u područje TMZ-a, na prvi pogled nude brze rezultate u olakšavanju simptoma. Pitanje koje se nameće jest mogu li se invazivnim metodama postići bolji rezultati u odnosu na konzervativni terapijski pristup te koliko je primjena ovakvih terapijskih metoda potkrijepljena znanstvenim dokazima o stvarnoj učinkovitosti.

Pacijentica koja je opisana pripada mlađoj populaciji za koju nisu uobičajene izrazite osteoartrične promjene. Simptomi poput bolova i ograničenja kretnji pojavili su se nakon prometne nezgode. Svrha terapije bila je ponajprije uklanjanje simptoma boli i povećanje raspona kretnji. Pacijentica je liječena neinvazivnim metodama koje su obuhvaćale kombinaciju fizikalne terapije i stabilizacijske udlage. Šest mjeseci nakon početka liječenja bila je gotovo bez tegoba. Na kontroli 2016. godine (tri godine poslije) i dalje nema značajnih simptoma. Kliničkim nalazom ustanovljene su krepitacije u području desnoga čeljusnog zgloba i blaža defleksija tijekom otvaranja, no takav nalaz nije činio poteškoće u normalnom funkcioniranju stomatognatog sustava.

Kada se razmišlja o drugim terapijskim metodama, kao što je primjerice aplikacija različitih terapijskih sredstava u područje zgloba, evidentno je da istraživanja predstavljena,

te force to the elevator muscles with the fingers, in order to increase the amount of mouth opening) (Figure 5). After 2 weeks patient reported significant relaxation of masticatory musculature. Stabilization splint is fabricated in the therapeutic centric relation position with increase of the vertical dimension of occlusion of 2 mm. Patient was instructed to wear a splint during night (Figure 6).

#### After-care

Follow up appointments were carried out at 1st, 3rd and 6th month of wearing the splint. At follow-up appointment after 6 months of regular wearing the splint the patient reported improvement of symptoms. Unassisted opening amounted to 35 mm while assisted opening amounted to 41 mm (Figure 7 a and b). Lateral movements were symmetrical (Figure 8 a and b). Occasional pain was still present only during chewing hard food (VAS = 2). Palpation of the lateral condyle pole was not painful.

At a 3-year recall appointment, in November 2016, the patient reported that by regular wearing a splint at night, pain occurs very rarely and only during chewing gum. However, if a splint is worn only occasionally, the headaches begun as well as difficulties while chewing hard food. Clinical examination showed mild uncorrected deviation during the opening, and the crepitus was still felt in the right joint.

#### Discussion

Osteoarthritis of the temporomandibular joint entails different variations in the pathophysiology, epidemiology, and progression of the disorder as well as signs and symptoms. It is important to mention that progression from the onset of symptoms and signs to clinically significant joint destruction may take years, but it can also happen very quickly (2). Because of the diverse range of incidence and manifestations, OA remains a condition whose diagnosis and treatment are the subject of discussion and research. Some methods, which include the application of corticosteroids, hyaluronic acid or the PRGF in the area of TMJ, at first glance offer rapid improvement of symptoms.

The question that arises is whether invasive methods can achieve better results than conservative therapeutic approaches (non-invasive methods) as well as how much are such therapeutic methods supported by scientific evidence of actual efficacy.

We presented young patient with severe osteoarthritic changes accompanied by pain and limited mouth opening that emerged after macrotrauma. The primary therapeutic goal was to resolve the pain and to increase the range of motion. Patient was treated with the combination of physical therapy and stabilization splint. At 6 months follow up patient reported improvement of symptoms. At a 3-year recall appointment the patient still had no significant symptoms. Clinical examination revealed crepitus in the right TMJ and mild uncorrected deviation during the opening, however, such a finding is not a problem for normal functioning of the patient.

When thinking of other therapeutic methods such as the application of various therapeutic agents in the area of the joint, it can be seen that research presented e.g. application

primjerice, aplikacijom PRGF-a u zglob nisu dala znatno drukčije rezultate od konzervativnih, neinvazivnih metoda. Giacomello i suradnici tijekom aplikacije PRGF-a dobili su nakon šest mjeseci povećanje raspona otvaranja usta od 9,38 mm (10), a kod pacijentice tretirane neinvazivnim metodama, predstavljene u ovome prikazu slučaja, povećanje raspona od 13 mm postignuto je nakon šest mjeseci. Bez obzira na uspješnost metoda koje obuhvaćaju aplikaciju PRGF-a u zglob, postavlja se pitanje bi li uopće, s obzirom na nejasnu etiologiju i cikličku prirodu poremećaja, takva poboljšanja bila trajna te ima li smisla koristiti se invazivnim metodama i penetrirati u područje zgloba ako se mirno stanje i poboljšanje funkcije mogu postići manje invazivnim načinima. Naime, vidljivo je iz slučaja mlade pacijentice da se potpuna bezbolnost uspjela postići i konzervativnim metodama, a raspon kretnji gotovo je potpuno vraćen na prijašnje stanje i više joj nije problem. Tomu u prilog ide i istraživanje Clarka i suradnika u kojem se navodi samo 8,6 posto potrebe za dodatnim terapijskim metodama nakon ponovnog pregleda pacijenta tretiranog neinvazivnim terapijskim metodama (18).

Također je važno istaknuti da je pacijentica u dobi od 21 godine pretrpjela makrotraumu koja je vjerojatno bila *trigger ili okidač* za razvoj simptoma. Kako je riječ o trajnoj ozljedi, simptome su mogli uzrokovati mišići u reaktivnom spazmu, a osteoarthritis je mogao biti slučajan nalaz koji pacijentici ne čini tegobe osim *pucketanja* (krepitus) koje se čuje pri naglom otvaranju usta. Krepitus je jedini karakterističan kriterij kliničke analize za dijagnostiku osteoartritisa, a rezultat je direktnog trenja među koštanim površinama (3). Incidencija krepitusa kod starijih adolescenata i mladih odraslih ljudi je, kako navode Solberg i suradnici, 12,5 posto (19). S obzirom na to da je postojalo ograničeno otvaranje usta, moglo se posumnjati i na udruženost pomaka zglobne pločice (dislokacija zglobne pločice bez redukcije) s OA-om (1), no za takvu dijagnozu potreban je pozitivan nalaz magnetske rezonancije (17).

## Zaključak

Na temelju opisanog slučaja pacijentice, možemo zaključiti da temporomandibularni zglob i sam OA-e, u pojedinim slučajevima, odlično reagira na neinvazivnu terapiju. Zadaća kliničara je prepoznati simptomatologiju te je olakšati kako bi pacijentu omogućili normalnu svakodnevnicu i usporili napredovanje osteoartritisa. Djelovanje je usmjereno na pokušaje da se utjecaje rizičnih čimbenika neinvazivnim metodama svede na najmanju moguću mjeru.

Pri liječenju TMP-a invazivne su metode prihvatljive kod vrlo malog postotka pacijenata koji ne odgovaraju na konzervativne, neinvazivne metode.

Simptomatski oblici osteoartritisa mogu se pojaviti i u mlađoj dobnoj skupini.

## Zahvala

Ovaj je rad, projektom IP-2014-09-3070, financirala – sufinancirala Hrvatska zaklada za znanost.

of PRGF in the joint did not give significantly different results compared to conservative, non-invasive methods. After PRGF application, Giacomello et al. an increase of 9.38 mm in the range of mouth opening after 6 months was found (10). Patient presented in our study, presented the increase in the range of ,mouth opening of 13 mm. Regardless of the success of the methods comprising application of the PRGF in the joint, the question arises, whether those improvement would be permanent and whether it makes sense to use invasive methods and penetrate the joint area if calm state and function improvement can be achieved through less invasive methods. It is evident from the case of a young patient, presented in our study, that complete absence of pain was also managed by conservative methods, and the range of motion is almost completely recovered and was no longer a problem to the patient.

It is also important to note that the 21-year-old patient had experienced macrotrauma which might be the trigger for the development of symptoms. Since this was a whiplash injury, symptoms could be the result of the muscles in reactive spasm, and osteoarthritis could be an incidental finding that does not present problems to the patient other than crepitus. Crepitus is the only distinctive criterion of clinical analysis for the diagnosis of osteoarthritis, and it's a direct result of the friction between the bone surfaces (3). The incidence of crepitus in older adolescents and young adults is 12.5%, as stated Solberg et al. (19). Given the fact that patient also presented a mouth limited opening, it could be suspected the disc displacement precede osteoarthritis (1). However, to confirm a diagnosis of disc displacement without reduction a positive MRI is required (17).

## Conclusion

We report on a 21-year-old woman with osteoarthritis of TMJ with a 3-year follow-up. Based on the case of a presented patient, we can conclude that OA of TMJ, in some cases, responds well to the non-invasive therapy. The task of the clinician is to identify the symptoms, relieve the pain in order to help the patient to achieve normal everyday life and slow the progression of osteoarthritis. The authors concluded that conservative treatment including counseling, exercises, occlusal splint therapy etc. should be considered as a first choice therapy, and in most cases the only therapy, for TMD pain because of their low risk of side effects.

When thinking about treatment of TMD invasive methods should be considered only in small percentage of patients that do not respond to less invasive therapy.

Symptomatic forms of osteoarthritis can also occur in younger age groups.

## Acknowledgement

This work has been fully supported by Croatian Science Foundation under the project (IP-2014-09-3070)).

**Abstract**

This paper describes a case of a young patient who sought help because of pain in the right temporomandibular joint (TMJ). She also reported increasing of pain during chewing. Clinical examination revealed limited mouth opening with uncorrected deviation to the ipsilateral side. Palpation of the lateral pole of the right condyle discovered crepitus, and maximum assisted opening elicited a report of "familiar pain". The diagnosis of osteoarthritis of the TMJ (RDC / TMD criteria, Axis I, Group III) was confirmed by CBCT of TMJ. There is no "gold standard" for the management of TMD, but the need for TMD treatment has to be based on precise indications related to the presence of pain, limitation in function of the lower jaw and signs of degenerative joint disease. Conservative, reversible therapeutic procedures are considered as the first choice for TMD treatment and their task is to improve the function of the entire masticatory system. In this case patient was treated with the combination of physical therapy and stabilization splint, in order to reduce the pain and restore the normal function of the lower jaw. At 6 months' follow-up symptoms have almost completely disappeared, while 3 years later, the patient still has no significant subjective symptoms. In the present case non-invasive therapy was sufficient to bring, otherwise recurrent nature of osteoarthritis, in complete remission and keep it like that for years.

Received: December 11, 2016

Accepted: July 21, 2017

**Address for correspondence**

Ema Vrbanović, DMD  
PhD student  
Franje Puškarića 32, 10250 Lučko  
Pho: +385 1989377644  
evrbanovic@sفزg.hr

**Key words**

Temporomandibular Joint Disorders; Osteoarthritis; Occlusal Splints; Physical Therapy Specialty

**References**

- Manfredini D. Current Concepts on Temporomandibular Disorders. London: Quintessence publishing Co, Inc; 2010.
- Tanaka E, Detamore MS, Mercuri LG. Degenerative disorders of the temporomandibular joint: etiology, diagnosis, and treatment. *J Dent Res.* 2008 Apr;87(4):296-307.
- Poveda-Roda R, Diaz-Fernandez JM, Hernandez-Bazan S, Jimenez-Soriano Y, Margaix M, Sarrion G. A review of temporomandibular joint disease (TMJD). Part II: Clinical and Radiological semiology. Morbidity processes. *Med Oral Patol Oral Cir Bucal.* 2008 Feb 1;13(2):E102-9.
- Schiffman E, Ohrbach R, Truelove E, Look J, Anderson G, Goulet JP, et al. Diagnostic Criteria for Temporomandibular Disorders (DC/TMD) for Clinical Research Applications: Recommendations of the International RDC/TMD Consortium Network and Orofacial pain Special Interest Group. *J Oral Facial Pain Headache.* 2014 Winter;28(1):6-27.
- Ahmad M, Schiffman EL. Temporomandibular Joint Disorders and Orofacial pain. *Dent Clin North Am.* 2016 Jan;60(1):105-24.
- Plesh O, Adams SH, Gansky SA. Temporomandibular joint and muscle disorder-type pain and comorbid pains in a national US sample. *J Orofac Pain.* 2011 Summer;25(3):190-8.
- Zarb G, and Carlsson G. TMD Disorders: Osteoarthritis. *J Orofac Pain.* 1999 Fall;13(4):295-306.
- Badel T, Alajbeg I, Marotti M, Kocijan Lovko S. Temporomandibular Joint disorder therapy by occlusal splint: A case report. *Acta Stomatol Croat.* 2008;42:283-91.
- Hansson, TL; Christensen, CA; Taylor, DL – editors. Physical therapy in craniomandibular disorders. Chicago: Quintessence Publishing Co; 1992.
- Giacomello M, Giacomello A, Mortellaro C, Gallesio G, Mozzati M. Temporomandibular Joint Disorders Treated With Articular Injection: The Effectiveness of Plasma Rich in Growth Factors-Endoret. *J Craniofac Surg.* 2015 May;26(3):709-13.
- Święchowicz S, Ostalsowska A, Kasperczyk A, Nowak D, Birkner E, Kasperczyk S. Evaluation of hyaluronic acid intraarticular injections in the treatment of primary and secondary osteoarthritis of the knee. *Pol Orthop Traumatol.* 2012 Oct 22;77:105-9.
- Kalladka M, Quek S, Heir G, Eliav E, Mupparapu M, Viswanath A. Temporomandibular Joint Osteoarthritis: Diagnosis and Long-Term Conservative Management: A Topic Review. *J Indian Prosthodont Soc.* 2014 Mar;14(1):6-15.
- Holmes MW, Bayliss MT, Muir H. Hyaluronic acid in human articular cartilage. Age-related changes in content and size. *Biochem J.* 1988 Mar 1;250(2):435-41.
- Yun PY, Kim YK. The role of facial trauma as a possible etiologic factor in temporomandibular joint disorder. *J Oral Maxillofac Surg.* 2005 Nov;63(11):1576-83.
- Bucholtz MR. TMJ and whiplash. *J Am Dent Assoc.* 2007 Nov;138(11):1422; author reply 1422.
- Milam SB. Pathogenesis of degenerative temporomandibular joint arthritides. *Odontology.* 2005 Sep;93(1):7-15.
- Yura S, Harada S, Kobayashi K. Diagnostic Accuracy on Magnetic Resonance Imaging for the Diagnosis of Osteoarthritis of the Temporomandibular Joint. *J Clin Diagn Res.* 2015 Jul;9(7):ZC95-7.
- Clark GT, Baba K, McCreary CP. Predicting the outcome of a Physical medicine treatment for temporomandibular disorder patients. *J Orofac Pain.* 2009 Summer;23:221-9.
- Solberg WK, Woo MW, Houtson JB (1979) Prevalence of mandibular dysfunction in young adults. *J Am Dent Assoc.* 1979 Jan;98(1):25-34.