



Joško Grgurević<sup>1</sup>, Ana Ivanišević Malčić<sup>2,5</sup>, Arjana Tambić Andrašević<sup>3</sup>, Goranka Prpić Mehičić<sup>2,5</sup>, Sania Kuzmac<sup>4</sup>, Silvana Jukić<sup>2,5</sup>

## Učestalost nalaza bakterijskog sadržaja u perzistentnim periapikalnim lezijama

### Frequency of Bacterial Content Finding in Persistent Periapical Lesions

<sup>1</sup> Zavod za oralnu kirurgiju Stomatološke poliklinike Zagreb

Department of Oral Surgery, Zagreb Dental Policlinic, Zagreb, Croatia

<sup>2</sup> Zavod za endodonciju i restaurativnu dentalnu medicinu Stomatološkog fakulteta Sveučilišta u Zagrebu

Department of Endodontics and Restorative Dentistry, School of Dental Medicine, University of Zagreb, Croatia

<sup>3</sup> Zavod za mikrobiologiju Medicinskog fakulteta Sveučilišta u Zagrebu

Department of Microbiology, School of Medicine University of Zagreb, Croatia

<sup>4</sup> Laboratorij za molekularnu imunologiju Medicinskog fakulteta Sveučilišta u Zagrebu

Laboratory for Molecular Immunology, School of Medicine University of Zagreb, Croatia

<sup>5</sup> Klinika za stomatologiju KBC-a Zagreb

University Clinical Hospital Center, Dental Clinic

#### Sažetak

**Ciljevi:** Svrha ovoga rada bila je odrediti postotak perzistentnih apikalnih lezija pozitivnih na bakterijske nukleinske kiseline, zatim s pomoću lančane reakcije polimeraze detektirati mikroorganizme u periapikalnim lezijama koje je teško kultivirati te ih povezati s endodontskim neuspjehom, kliničkih simptomima i dijabetesom. **Materijali i postupci:** Uzorci perzistentnih apikalnih lezija skupljeni su tijekom apikotomije. Bakterijska ubikvitarna početnica 16S rRNK rabljena je za otkrivanje 16S ribosomskog RNK u 36 uzoraka. PCR usmjeren na pojedine vrste proveden je s pomoću početnica za 16S rRNK gene *Prevotella nigrescens*, *Pseudoramibactera alactolytica* i *Propionibacterium propionicum*. **Rezultati:** Šest uzoraka (16,67 %) bilo je pozitivno na bakterijski ribosomski RNK. *Pseudoramibacter alactolyticus* detektiran je u trima uzorcima. *Propionibacterium propionicum* i *Prevotella nigrescens* detektirani su svaki u po jednom uzorku. Prevalencija infekcije ovih lezija *P. intermedia*, *P. propionicum* i *P. alactolyticusom* niska je. Provedeno istraživanje nije dalo dostatne podatke o povezanosti ekstraradikularne infekcije s dijabetesom melitusom i kliničkim simptomima. **Zaključci:** Apikalne lezije koje perzistiraju nakon endodontskog liječenja mogu, uz *Actinomyces* i *Propionicum species*, sadržavati i druge mikroorganizme.

**Zaprimljen:** 13. svibnja 2017.

**Prihvaćen:** 31. srpnja 2017.

#### Adresa za dopisivanje

Ana Ivanišević Malčić  
Sveučilište u Zagrebu, Stomatološki  
Fakultet

Zavod za endodonciju i restaurativnu  
dentalnu medicinu

Gundulićeva 5, 10 000 Zagreb,  
Hrvatska

tel: 1 4802 126; +385 99 4030 549

faks: 1 4802 159

aivanisevic@sfzg.hr

#### Ključne riječi

korijenski kanal, oblikovanje; neuspjeh u liječenju; periapikalni apsces; bakterijski RNK; 16S ribosomski RNK; lančana reakcija polimerazom

#### Uvod

Perzistencija apikalnih lezija nakon endodontskog liječenja povezana je s intraradikularnom infekcijom, ekstraradikularnom infekcijom, reakcijom na strano tijelo, stvaranjem ciste i cijeljenjem vezivnim ožiljkom (1, 2).

Mnogobrojne studije bavile su se otkrivanjem i identifikacijom mikroorganizama u napunjenom korijenskom kanalu liječenoga zuba (3, 4, 5, 6, 7), a perzistencija mikroorganizama u apikalnom dijelu korijenskog kanala prepoznata je kao glavni uzrok neuspjeha endodontske terapije, čak i nakon *lege artis* provedenih endodontskih postupaka (1). To se može dogoditi zbog nemogućnosti endodontskih instrumenata i sredstava za ispiranje da dosegnu sve dijelove sustava korijenskog kanala i učinkovito uklone sve mikroorganizme.

#### Introduction

The persistence of apical lesions after endodontic treatment is associated with intraradicular infection, extraradicular infection, foreign body reaction, cyst formation and fibrous scar tissue healing (1,2).

A number of studies dealt with the detection and identification of microorganisms in the root canal of root-filled teeth (3,4,5,6,7), and the persistence of microorganisms in the apical part of the root canal was recognized as the major cause of endodontic treatment failures, even after *lege artis* performed endodontic procedures (1). This may occur due to inability of endodontic instruments and irrigants to reach all parts of the root canal system and effectively remove microorganisms. Root canal microflora between primary endodon-

me. Mikroflora korijenskog kanala razlikuje se kod primarnih endodoncija i u slučajevima revizije (8). Intraradikalna flora zuba povezanih s perzistentnim apikalnim parodontitisom sastoji se od manje vrsta, i to prevladavajuće gram-pozitivnih. U tim je slučajevima pronađen velik udjel enterokoka (7). Drugi mikroorganizam koji može preživjeti kao monoinfekcija, te čak ući u dentinske tubuluse, jest *Candida albicans* (7). Općenito, u slučaju revizije mikroorganizmi mogu preživjeti s malo nutrijenta, otporni su na intrakanalne medikamente i sredstva za ispiranje (kalcijev hidroksid, natrijev hipoklorit), stvaraju biofilmove u kanalima, invadiraju dentinske tubuluse i metaboliziraju intratubularnu tekućinu i tekućinu iz parodontnog ligamenta, prijanjaju na kolagen, prelaze u vijabilno, ali nekultivabilno stanje i stječu rezistenciju na antibiotike (9).

Intraradikalni mikroorganizmi mogu svladati periapikalnu obrambenu prepreku i uspostaviti ekstraradikalnu infekciju koja može uzrokovati akutni apikalni apsces. Mikroorganizmi koji prevladavaju u ekstraradikalnoj infekciji anaerobne su bakterije poput *Actinomyces* spp., *Propionibacterium propionicum*, *Treponema* spp., *Porphyromonas endodontalis*, *Porphyromonas gingivalis*, *Treponema forsythia*, *Prevotella* spp. i *Fusobacterium nucleatum* (10, 11). Klasične histološke studije dosljedno su pokazale prisutnost mikroorganizama u periapikalnom tkivu slučajeva s kliničkim znakovima i simptomima poput akutnog apscesa i drenirajućeg sinusnog trakta, no asimptomatski slučajevi perzistentnih periapikalnih lezija općenito nisu bili inficirani (1). No u nekim radovima navodi se postojanje ekstraradikalnih biofilмова kod asimptomatskog periapikalnog parodontitisa i kroničnog apikalnog apscesa sa sinusnim traktom (12, 13). Također je u nekim radovima mikrobiološkim i molekularnim postupcima nađena ekstraradikalna infekcija u slučaju asimptomatskih periapikalnih lezija koje perzistiraju nakon ispravne endodoncije (10, 11).

Razumijevanje mikroorganizama koji uzrokuju perzistentne apikalne lezije pomaže nam pri odabiru intrakanalnog medikamenta i sredstava za ispiranje tijekom postupka ponovljenog liječenja, ili u odluci o potrebi kirurškog postupka. Svrha ovog istraživanja bila je PCR-om detektirati mikroorganizme u periapikalnim lezijama koje je teško kultivirati te ih povezati s endodontskim neuspjehom, kliničkim simptomima i dijabetesom.

## Materijali i postupci

### Pacijenti

Uzorak se sastojao od 48 pacijenata, ali je samo njih 36 u dobi od 24 do 58 godina (19 muškaraca i 17 žena) bilo prikladno za analizu. Pacijenti su upućeni u Zavod za oralnu kirurgiju Poliklinike Zagreb na zahvat apikotomije zbog perzistentnog apikalnog parodontitisa čija je dijagnoza postavljena prije operacije na temelju kliničkoga i radiološkoga nalaza. Etički protokol za istraživanje odobrilo je Etičko povjerenstvo Stomatološkog fakulteta Sveučilišta u Zagrebu. Pacijenti su potpisali informirani pristanak, a prije postupka apikotomije uzeta im je detaljna medicinska i stomatološka anamneza. Zabilježeno je boluje li pacijent od dijabetesa melitusa. Paci-

tic cases and retreatment cases differs (8). Intraradicular flora of the teeth associated with persistent apical periodontitis consists of a small number of species, predominantly Gram-positive ones. A high proportion of enterococci have been reported in such cases (7). Another microorganism which can survive as a monoinfection, and even invade dentinal tubules is *Candida albicans* (7). Generally, the microorganisms in retreatment cases can survive in poor nutrient environment, resist intracanal medications and irrigants (calcium hydroxide, sodium hypochlorite), form biofilms in canals, invade dentinal tubules and metabolize fluids within them and from periodontal ligament, adhere to collagen, convert into a viable but non-cultivable state and acquire antibiotic resistance (9).

Intraradicular microorganisms can overcome periapical defense barrier and establish extraradicular infection, which may cause acute apical abscess. Microorganisms that prevail in extraradicular infection are anaerobic bacteria such as *Actinomyces* spp., *Propionibacterium propionicum*, *Treponema* spp., *Porphyromonas endodontalis*, *Porphyromonas gingivalis*, *Treponema forsythia*, *Prevotella* spp. and *Fusobacterium nucleatum* (10, 11). In classic histology studies, microorganisms were consistently present in the periapical tissue of cases with clinical signs and symptoms such as acute abscesses and draining sinus tracts, but asymptomatic persistent periapical lesions were generally not infected (1). There are, however, reports on extraradicular biofilms in asymptomatic periapical periodontitis and chronic apical abscesses with sinus tracts (12, 13). There are, also, reports on extraradicular infection of asymptomatic periapical lesions persisting after proper endodontics using microbial culture and molecular methods, where strict aseptic sampling procedures were used (10, 11).

A clear understanding of the etiology and pathogenesis of the microbes causing persistent endodontic lesion helps in deciding on the use of intracanal medicaments and irrigants in endodontic retreatment cases with periapical lesions, or whether apical surgery should be preferred. The aim of this study was to detect microorganisms difficult to cultivate in periapical lesions by PCR, and to relate them to endodontic failure, clinical symptoms, and diabetes mellitus.

## Materials and methods

### Patients

The sample consisted of 48 patients, but only the samples of 36 patients between 24-58 years of age (19 males and 17 females) were adequate for analysis. The patients were referred to the Department of Oral Surgery at Dental Clinic Zagreb for apicoectomy due to persistent apical periodontitis, which had been diagnosed preoperatively based on clinical and radiologic findings. The Ethical protocol for the study was approved by the Ethics Committee of the School of Dental Medicine, University of Zagreb. The patients signed the informed consent and a detailed medical and dental history was taken prior to the apicoectomy procedure. It was record-

jenti su kategorizirani kao simptomatski ako je ukupan broj bodova na vizualno-analognj ljestvici od 1 do 100 iznosio  $\geq 30$ , tj. kada su bili otečeni ili su osjećali umjerenu do jaku bol na palpaciju ili perkusiju. Kriteriji za uključenje bili su:

- (i) adekvatno endodontsko liječenje s perzistentnom ili postendodontskom periapikalnom lezijom
- (ii) revizija endodontskog liječenja nije bila moguća zbog intraradikularne nadogradnje.

Kriteriji za procjenu endodontskog liječenja kao adekvatnoga:

- punjenje do 2 mm kraće, radiološki homogeno punjenje korijenskog kanala.

Kriteriji za isključivanje bili su:

- (i) zubi s parodontnim džepovima
- (ii) liječenje antibioticima u posljednja tri mjeseca
- (iii) ozbiljne sistemske bolesti
- (iv) trudnice ili dojilje
- (v) sudjelovanje u drugim kliničkim istraživanjima u posljednja tri mjeseca.

#### Uzorci tkiva

Uzorci perzistentnih apikalnih lezija skupljani su tijekom postupaka apikotomije. Pacijenti su ispirali usta 0,2-postotnom otopinom klorheksidin-glukonata 30 sekunda neposredno prije operacije. Učinjena je Nowak-Peterova incizija i odignut mukoperiostalni režanj u punoj debljini. Nakon toga je operativno polje isprano sterilnom fiziološkom otopinom i pristupljeno je apeksu s pomoću sterilnoga karbidnog svrdla. Cijela je lezija izljuštena te je učinjena apikotomija Lindemanovim karbidnim svrdlom. Uzorci periapikalnog tkiva prebačeni su u litički pufer od ekstrakcijskoga kita QiaAmp<sup>†</sup> DNA Mini Kit (Qiagen, GmbH, Njemačka) prema uputama proizvođača te pohranjeni u tekući dušik, pa u kriotubice na  $-80^{\circ}\text{C}$  prije ekstrakcije DNK.

#### Ekstrakcija DNK

Ekstrakcija DNK provedena je komercijalnim kitom (Qiagen, Hilden, Njemačka) prema uputama proizvođača. Zatim su uzorci izvađeni iz kriotubice, zagrijani na sobnu temperaturu ( $20 - 25^{\circ}\text{C}$ ) i sterilnim škarama izrezani na manje dijelove. Manje od 25 mg svakog uzorka stavljeno je u tubu od 1,5 ml (Eppendorf Safe-Lock Tubes, Eppendorf, Njemačka) s prije pripremljenom enzimskom otopinom (20 mg/ml lizozima; 29 mM TrisHCl, 2 mM EDTA; 1,2 % tritione) za degradaciju zida gram-pozitivnih bakterija, a zatim su uzorci jedan sat inkubirani na  $37^{\circ}\text{C}$ .

Zatim je 180  $\mu\text{L}$  pufera ATL (Qiagen) i 20  $\mu\text{L}$  proteinaze K (20 mg/ml) dodano zbog degradacije proteina, a uzorci su inkubirani 24 sata na  $56^{\circ}\text{C}$ . Nakon toga su uzorci centrifugirani na 8000 RPM (Sigma 113, Sigma-Aldrich, Njemačka). Nadalje, dodano im je 200  $\mu\text{L}$  pufera AL-a iz kita, te su vorteksirani 15 sekunda i inkubirani 10 minuta na  $70^{\circ}\text{C}$ . Zatim je dodano 200  $\mu\text{L}$  etanola i svaki je uzorak ponovno centrifugiran 15 sekunda na 8000 RPM. DNK je izoliran dodavanjem lizata Qiagenovim stupcima kako je opisao proizvođač. Bakterijski DNK je eluiran s 200  $\mu\text{L}$  AE pufera (Qiagen): jednodominantnom inkubacijom na sobnoj temperaturi i jedno-

ed whether a patient suffered from diabetes mellitus. The patients were categorized as symptomatic if they scored  $\geq 30$  on visual analogue scale from 1-100 i.e. they were swollen or experienced moderate to strong pain to palpation or percussion. The inclusion criteria were: (i) adequate endodontic treatment with persistent or postendodontically developed periapical lesion, (ii) revision of the endodontic treatment was not possible due to intraradicular post. The criteria for considering endodontic procedure as adequate were: root canal filling up to 2mm short, and radiologically homogenous root canal filling.

The exclusion criteria were: (i) teeth with periodontal pockets, (ii) treatment with antibiotics within the last three months, (iii) serious systemic diseases, (iv) pregnant or breast feeding female patients, (v) participation in other clinical studies within the last three months.

#### Tissue samples

The samples of persistent apical lesions were collected during apicoectomy procedures. The patients washed their mouth with 0.2% chlorhexidine gluconate solution for 30 seconds prior to surgery. The Nowak-Peter incision was applied and full-thickness mucoperiosteal flap was reflected. The operative field was subsequently washed with sterile saline and the apex was approached using sterile carbide bur. The entire lesion was enucleated and apicectomy was performed using Lindeman carbide bur. Periapical tissue samples were transferred to lysis buffer from the extraction kit QiaAmp<sup>†</sup> DNA Mini Kit (Qiagen, GmbH, Germany) according to the manufacturer instruction, and subsequently stored in liquid nitrogen, and then in criotubes at  $-80^{\circ}\text{C}$  prior to DNA extraction.

#### DNA extraction

DNA extraction was performed using commercial kit (Qiagen, Hilden, Germany) according to the manufacturer's instructions. The samples were taken out of the criotubes, warmed to room temperature ( $20-25^{\circ}\text{C}$ ), and cut to smaller pieces using sterile scissors. Less than 25 mg of each sample was placed into 1,5 ml tube (Eppendorf Safe-Lock Tubes, Eppendorf, Germany) with previously prepared enzymatic solution (20 mg/ml lysosime; 29mM TrisHCl, 2 mM EDTA; 1,2% tritione) for the degradation of gram positive bacteria wall. Subsequently, the samples were incubated for 1 h at  $37^{\circ}\text{C}$ .

After that, 180  $\mu\text{L}$  ATL buffer (Qiagen) and 20  $\mu\text{L}$  proteinase K (20 mg/ml) were added for protein degradation, and samples were incubated for 24 h at  $56^{\circ}\text{C}$ . The samples were then centrifuged at 8000 RPM (Sigma 113, Sigma-Aldrich, Germany). Next, 200  $\mu\text{L}$  of AL buffer from the kit was added, vortexed for 15 seconds, and incubated for 10 minutes at  $70^{\circ}\text{C}$ . Then 200  $\mu\text{L}$  of ethanol was added and each sample was again centrifuged for 15 seconds at 8000 RPM. DNA was isolated by adding the lysate to the Qiagen columns as described by the manufacturer. Bacterial DNA

minutnim centrifugiranjem na 8000 RPM. Postupak je ponovljen dva puta te su talozi na dva sata stavljeni u koncentrator (Concentrator plus, Eppendorf, Njemačka). Ekstrakti DNK pohranjeni su na  $-20^{\circ}\text{C}$ .

### Amplifikacija DNK

Na početku je korištena ubikvitarna bakterijska početnica 16S rRNK za detekciju 16S ribosomskog RNK u svih 36 uzoraka. Smjesa za PCR sadržavala je oligonukleotidne početnice specifične za rDNK.

Kvaliteta ekstrahirana DNK provjerena je spektrofotometrijski (NanoDrop 1000 Spectrophotometer, Thermo Fisher Scientific, Wilmington, SAD). PCR specifičan za pojedine vrste proveden je s početnicama za 16S rRNK gene *Prevotella Nigrescens* (F:5'ATG AAA CAA AGG TTT TCC GGT AAG3' R:5'CCC ACG TCT CTG TGG GCT GCG A3'), *Pseudoramibactera alactolyticusa* (F:5'CGA ATA AGT CAG TGC CGG3' R:5'CTT CGC TTC CCT TTG TTC AG3') i *Propionobacterium propionicum* (F:5'GAC GGT AGC AGT AGA AGA AGC AC3' R:5'CTG TAA ACC GAC CAA AAA GG3') (4, 15).

Svi PCR pokusi obavljani su u 50  $\mu\text{L}$  reakcijske smjese koja je sadržavala 1  $\mu\text{M}$  specifične početnice, 2 mM  $\text{MgCl}_2$ , 0,2 mM dNTP, 0,25  $\mu\text{L}$  AmpliTaq Gold DNK polimeraze i 10  $\mu\text{L}$  ekstrahirane DNK (svi reagensi od proizvođača Applied Biosystems, Lewinsville, SAD).

Amplifikacija je provedena u termociklatoru (Applied Biosystems 2720 Thermal Cycler, Singapur) s početnom petominutnom denaturacijom na  $95^{\circ}\text{C}$ , zatim je slijedilo 36 denaturacijskih ciklusa na  $95^{\circ}\text{C}$  tijekom 30 sekunda, jednodominutno vezanje početnice na  $55^{\circ}\text{C}$ , jednodominutna ekstenzija na  $72^{\circ}\text{C}$  (osim za *Prevotellu nigrescens*, 2 min.) te završni dvominutni korak na  $72^{\circ}\text{C}$  (osim za *Prevotella nigrescens*, 10 min.).

Produkti PCR-a analizirani su s pomoću elektroforeze na 2-postotnom agaroznom gelu na 5 V/cm. Agarozni gel napravljen je otapanjem agaroze u Tris-acetat EDTA puferu u mikrovalnoj pećnici do ključanja, zatim je ohlađen na temperaturu od otprilike  $50^{\circ}\text{C}$  i dodan mu je etidijev bromid u koncentraciji od 0,5  $\mu\text{g}/\text{ml}$ . Gel je zatim stvrdnut na sobnoj temperaturi i stavljen u 1X TAE pufer. Produkti amplifikacije pomiješani su s puferom s brom-fenolnim bojilom (BlueJuice, invitrogen, Kalifornija, SAD) u omjeru 6 prema 1. Gel je fotografiran Kodakovom DC 290 Zoom digitalnom kamerom (Kodak corp, Rochester, New York, SAD) pod UV svjetlom ( $\lambda = 302\text{ nm}$ ). Za određivanje duljine bakterijskoga DNK lanca, korišteni su komercijalni standardi s DNK lancima duljina od 67 do 1114 parova baza (Roche, Indianapolis, SAD).

### Statistička analiza

Dobiveni podaci analizirani su GraphPad InStat 3 programom (GraphPad Software, Inc, La Jolla, SAD). Vjerojatnost povezanosti pojedinih mikroorganizama s dijabetesom melitusom i/ili specifičnim simptomom određena je Fisherovim egzaktnim testom ( $p < 0,05$ ).

was eluted with 200  $\mu\text{L}$  AE buffer (Qiagen): 1 minute incubation at room temperature and a centrifugation was performed at 8000 RPM for 1 min. The procedure was repeated twice and the pallets were placed in concentrator (Concentrator plus, Eppendorf, Germany) for two hours. DNA extracts were stored at  $-20^{\circ}\text{C}$ .

### DNA amplification

At the beginning, the bacterial ubiquitous 16S rRNA primer was used to detect the 16S ribosomal RNA in all 36 samples. Subsequently, a PCR mixture with oligonucleotide primers specific for rDNAs was used.

The quality of extracted DNA was checked spectrophotometrically (NanoDrop 1000 Spectrophotometer, Thermo Fisher Scientific, Wilmington, USA). A species-specific PCR was performed with primers targeted to the bacterial 16S rRNA genes of *Prevotella Nigrescens* (F:5'ATG AAA CAA AGG TTT TCC GGT AAG3' R:5'CCC ACG TCT CTG TGG GCT GCG A3'), *Pseudoramibacter alactolyticus* (F:5'CGA ATA AGT CAG TGC CGG3' R:5'CTT CGC TTC CCT TTG TTC AG3') and *Propionobacterium propionicum* (F:5'GAC GGT AGC AGT AGA AGA AGC AC3' R:5'CTG TAA ACC GAC CAA AAA GG3') (4,15).

All PCR essays were performed in a 50  $\mu\text{L}$  reaction mixture containing 1  $\mu\text{M}$  of each specific primer, 2 mM  $\text{MgCl}_2$ , 0.2 mM dNTP, the 0.25  $\mu\text{L}$  AmpliTaq Gold DNA polymerase, and 10  $\mu\text{L}$  extracted DNA (all reagents from Applied Biosystems, Lewinsville, USA).

Amplification was carried out in a thermal cycler (Applied Biosystems 2720 Thermal Cycler, Singapore) with an initial denaturation at  $95^{\circ}\text{C}$  for 5 min followed by 36 cycles of denaturation at  $95^{\circ}\text{C}$  for 30 s, primer annealing step at  $55^{\circ}\text{C}$  for 1 min, an extension step at  $72^{\circ}\text{C}$  for 1 min (apart from 2 min for *Prevotella nigrescens*), and a final step at  $72^{\circ}\text{C}$  for 2 min (except 10 min for *Prevotella nigrescens*).

PCR products were examined by 2% agarose gel electrophoresis performed at 5 V/cm. Agarose gel was made by melting agarose in Tris-acetate EDTA buffer in the microwave oven until boiling. After that, it cooled down to the temperature of approximately  $50^{\circ}\text{C}$ , and ethidium bromide of 0.5  $\mu\text{g}/\text{ml}$  concentration was added. The gel was then solidified at room temperature and placed in 1X TAE buffer. Amplification products were mixed with a buffer with bromophenol- blue (BlueJuice, invitrogen, California, USA) in a ratio 6 to 1. The gel was photographed using Kodak DC 290 Zoom Digital Camera (Kodak corp, Rochester, New York, United States) under UV light ( $\lambda=302\text{ nm}$ ). For determining the length of bacterial DNA strand, a commercial standard with DNA strands ranging in length from 67 to 1114 bp was used (Roche, Indianapolis, USA).

### Statistical Analysis

The obtained data were analysed using GraphPad InStat 3 program (GraphPad Software, Inc, La Jolla, USA). Possible associations between certain microorganism and diabetes mellitus and/or specific symptom were determined using exact Fisher test ( $p < 0.05$ ).

## Rezultati

Od 36 pacijenata, 52,78 posto (19) bili su muškarci, a 47,22 posto (17) žene. Dob je bila u rasponu od 25 do 65 godina (prosjek 44,6 godina).

16S ribosomski RNK detektiran je u šest uzoraka (16,67 %). Trideset uzoraka bilo je negativno na bakterije (83,33 %) (slika 1.).

Šest pozitivnih uzoraka dalje je testirano na tri anaerobne bakterijske vrste – *Prevotella nigrescens* (g-, bacil), *Pseudoramibacter alactolyticus* (g+ bacil) i *Propionibacterium propionicum* (g+ bacil).

Jedan uzorak bio je pozitivan na *Pseudoramibacter alactolyticus* i *Propionibacterium propionicum*, jedan je bio pozitivan na *Prevotellu nigrescens* i *Pseudoramibacter alactolyticus*, a jedan samo na *Pseudoramibacter alactolyticus*.

Nije bilo statistički značajne povezanosti između ikoje od triju mikroorganizama s dijabetesom melitusom (tablica 2.) ili simptomima (tablica 3.). No uzimajući u obzir mali broj inficiranih uzoraka tkiva, teško je rezultate ove statističke analize smatrati visoko relevantnima. Zbog te činjenice provedeno istraživanje nije dalo dovoljno podataka o povezanosti ekstradikularne infekcije s dijabetesom melitusom i simptomima.

## Results

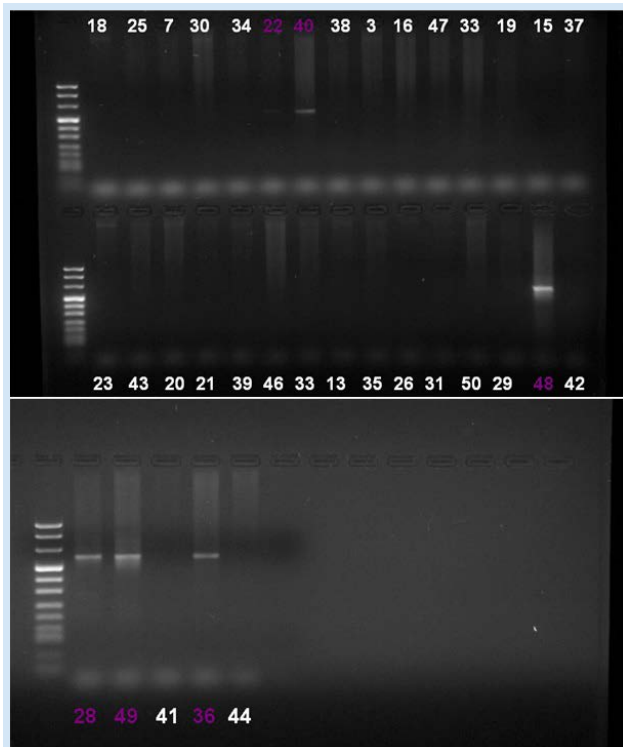
Out of 36 patients, 19 (52.78) were male, and 17(47.22%) were female. Their age range was 25-65 years; the average age was 44.6 years.

16S ribosomal RNA was detected in six samples (16.67%). Thirty samples, (83.33%), were negative for the presence of bacteria (Figure 1).

The six positive samples were further tested for the presence of three anaerobic bacterial species: *Prevotella nigrescens* (g-, bacillus), *Pseudoramibacter alactolyticus* (g+ bacillus) and *Propionibacterium propionicum* (g+ bacillus).

One sample was positive for *Pseudoramibacter alactolyticus* and *Propionibacterium propionicum*, one sample was positive for *Prevotella nigrescens* and *Pseudoramibacter alactolyticus*, while one sample was positive only for *Pseudoramibacter alactolyticus*.

There was no statistically significant correlation between either of three microorganisms and diabetes mellitus (Table 2) or symptoms (Table 3). However, considering a low number of infected tissue samples, it is hard to consider the results of this particular statistical analysis as highly relevant. Due to this fact, this study did not give sufficient data about extraradicular infection and its connection with diabetes mellitus and symptoms.



**Slika 1.** Ubikvitarni bakterijski primer test na agaroznim gelovima – 2 %, DNK je vizualiziran etidijevim bromidom (veličina fragmenta 602 pb, prema Ashimoto i sur. 1996.); šest uzoraka (22, 40, 48, 28, 49, 36) bilo je pozitivno i dalje analizirano na prisutnost *Prevotelle nigrescens*, *Pseudoramibacteria alactolyticusa* i *Propionibacterium propionicum*

**Figure 1** Ubiquitous bacterial primer test on agarose gels- 2%, DNA was visualized by ethidium-bromide (fragment size 602 pb, according to Ashimoto et al. 1996). Six samples (22, 40, 48, 28, 49, 36) were positive, and were further tested for presence of *Prevotella nigrescens*, *Pseudoramibacter alactolyticus* and *Propionibacterium propionicum*.

**Tablica 1.** Broj uzoraka pozitivnih na pojedini mikroorganizam  
**Table 1** Number of samples that were positive for a certain microorganism.

Mikroorganizam • Microorganism	Broj pozitivnih uzoraka • Number of positive samples	Gram	Aerob • Aerobe	Oblik • Shape
<i>Prevotella nigrescens</i>	1	Gram-	-	Bacillus
<i>Pseudoramibacter alactolyticus</i>	3	Gram+	-	Bacillus
<i>Propionibacterium propionicum</i>	1	Gram+	-	Bacillus

**Tablica 2.** Povezanost pojedinog mikroorganizma s dijabetesom melitusom  
**Table 2** Correlation between certain microorganisms and diabetes mellitus

Mikroorganizam • Microorganism	Omjer • Odds ratio	95%-tni interval pouzdanosti • Confidence interval 95%	P vrijednost • P value
<i>Prevotella nigrescens</i>	2.70	0.10-74.73	1.00
<i>Pseudoramibacter alactolyticus</i>	1.10	0.05-24.36	1.00
<i>Propionibacterium propionicum</i>	2.70	0.10-74.73	1.00

**Tablica 3.** Povezanost pojedinog mikroorganizma sa simptomima  
**Table 3** Correlation between certain microorganisms and symptoms

Mikroorganizam • Microorganism	Omjer • Odds ratio	95%-tni interval pouzdanosti • Confidence interval 95%	P vrijednost • P value
<i>Prevotella nigrescens</i>	1.11	0.04-29.32	1.00
<i>Pseudoramibacter alactolyticus</i>	0.45	0.02-9.45	1.00
<i>Propionibacterium propionicum</i>	1.11	0.04-29.32	1.00

## Rasprava

Uloga mikroorganizama u primarnim endodontskim infekcijama prije je potvrđena (16). Također je zaostala intraradikalna infekcija prepoznata kao glavni uzrok perzistentnog apikalnog parodontitisa (1). Uz intraradikalnu infekciju, izostanak poslijeendodontskog cijeljenja može biti uzrokovan aloplastičnim materijalom u periapeksu (npr. ekstrudirani materijali za punjenje korijenskog kanala), akumulacijom kristala kolesterola i formiranjem prave ciste. Osim toga, uzroci periapikalne radiolucencije mogu biti cijeljenje ožiljnim tkivom i ekstraradikalna infekcija koja je prema Nairu (1) općenito u obliku periapikalne aktinomikoze. Ipak, neke su studije, koristeći se skeniranjem elektronskom mikroskopijom, pokazale da postoje biofilmovi na vanjskoj – ekstraradikalnoj strani korijena te da *Actinomyces species* nisu jedini infektivni organizmi nađeni u nezacjeljenoj periapikalnoj leziji (13). Wang i suradnici (13) istraživali su izvan-korijensku bakterijsku floru u lezijama perzistentnog apikalnog parodontitisa i, premda je prevalencija *Actinomyces sp.* i *Propionibacterium* bila najveća, bilo je više bakterijskih vrsta, uključujući *Prevotella sp.*, *Streptococcus*, *Porphyromonas endodontalis* i *Burkholderia*. U slučaju vitalnih i nekrotičnih pulpi nije bilo mikroorganizama na ekstraradikalnim ploham, iz čega se moglo zaključiti da je ekstraradikalni biofilm povezan s perzistentnom infekcijom nakon neuspješne endodontije (13).

Mi smo odabrali ispitati uzorke tkiva zatvorenih periapikalnih lezija na prisutnost triju mikroorganizama izoliranih iz korijenskih kanala s nekrotičnom pulpom i/ili korijenskih kanala neuspješno endodontski liječenih zuba. *Prevotella nigrescens* odabrana je kao reprezentativna bakterija visoko prevalentnih bakterija u korijenskih kanalima s nekrotičnom

## Discussion

The role of microorganisms in primary endodontic infections was early established (16). Also, residual intraradicular infection was recognized as the major cause of persistent apical periodontitis (1). Apart from intraradicular infection, the absence of post-treatment healing can be caused by: aloplastic material in periapex (e.g. extruded root canal filling materials), cholesterol crystals accumulations, and true cysts formation. Also, periapical radiolucency can be caused by scar tissue healing and extraradicular infection that is according to Nair (1) generally in the form of periapical actinomycosis. Nevertheless, there are studies that have shown the presence of biofilms on the outer- extraradicular side of the root using scanning electron microscope, and studies reporting that *Actinomyces species* are not the only infective agents found in unresolved periapical lesions (13). Wang et al. (13) investigated extraradicular bacterial flora in persistent apical periodontitis, and although the prevalences of *Actinomyces sp.* and *Propionibacterium* were the highest, bacterial species were multiple and included *Prevotella sp.*, *Streptococcus*, *Porphyromonas endodontalis*, and *Burkholderia*. In cases with vital and necrotic pulps there were no microorganisms on extraradicular surfaces, which suggested that extraradicular biofilm is associated with persistent infection after failed endodontics (13).

We chose to evaluate the tissue samples of closed periapical lesions for the presence of 3 microorganisms that were reported to be isolated from root canals with necrotic pulp and/or from the root canals of the teeth with failed endodontic procedure. *Prevotella Nigrescens* was chosen as a representative of bacterial species that are highly prevalent in root canals with necrotic pulp, and frequently isolated in symptomatic

pulpom i često izolirana u simptomatskim endodontskim infekcijama (17). *Pseudoramibacter alactolyticus* i *Propionibacterium propionicum* detektirani su u korijenskim kanalima pacijenata nakon neuspješnog endodontskog liječenja (4).

Isključeni su bili pacijenti koji su uzimali antibiotike unatrag tri mjeseca zbog mogućeg smanjenja broja anaerobnih bakterija uzrokovanog antibiotikom. U istraživanju se željelo proučiti mikrobiološke aspekte *zatvorenih* periapikalnih transparenacija koje perzistiraju nakon endodontskog tretmana, tj. onih koje ne komuniciraju s parodontom ili usnom šupljinom putem karijesa, neadekvatno kondenziranog punjenja korijenskog kanala, neispunjenih korijenskih kanala i propuštajuće koronarne restauracije. Fraktura korijena, fistula, komunikacija s maksilarnim sinusom i mobilnost zuba također upućuju na komunikaciju periapikalne lezije s oralnim ekosustavom te su i takvi slučajevi bili isključeni iz istraživanja, prije operativnog postupka ili tijekom njega.

Potrebno je istaknuti da smo posebno pazili da se uzorci ne kontaminiraju oralnim bakterijama te smo primjenjivali pravila aseptičnoga kirurškog uzorkovanja. Pri odizanju mukoperiostalnog reznja i pristupanja periapikalnom području učinjena je marginalna incizija jer se prije pokazalo da rizik od kontaminacije nije značajno veći nego u slučaju submarginalne incizije, ali je značajno manji nego u slučaju Partschove incizije (18). Sluznica je isprana 0,2-postotnim klorheksidin-glukonatom te su kultivirani mikrobiološki uzorci. Premda je kost kod marginalne incizije bila inficirana u 100 posto uzoraka, a u slučaju submarginalne incizije u tek 20 posto, omjer periapikalnih uzoraka pozitivnih na mikroorganizme nije se značajno razlikovao između dviju skupina, a kultivirani mikroorganizmi uzeti sa sluznice, kosti i periapikalnog tkiva istog pacijenta razlikovali su se. Autori su zaključili da odizanje mukoperiostalnog reznja nije odgovorno za pozitivan nalaz mikroorganizama. Ipak, čak i kada se pažljivo izbjegne kontaminacija iz usta, lezija se može inficirati intraradikalnim bakterijama tijekom uzorkovanja, a pozitivni nalaz mikroorganizama u takvim se uzorcima može opisati kao ekstraradikalna infekcija (1). Osim spomenute kontaminacije uzoraka, detekcija mikroorganizama u uzorcima periapikalnoga tkiva molekularnim postupcima poput PCR-a, također je upitna. Primjenjujući postupak PCR-a, nemoguće je razlikovati vijabilne od nevijabilnih mikroorganizama te razlučiti mikrobe i njihove strukturne elemente u fagocitima od izvanstaničnih mikroorganizama (1, 4). Zato molekularni postupci, premda prilično sofisticirani, ne rješavaju problem potencijalne kontaminacije periapikalne lezije tijekom uzimanja uzorka.

Korištenje univerzalne bakterijske početnice u našem istraživanju otkrilo je da je 16,67 posto uzoraka inficirano bakterijama. Naši rezultati također sugeriraju nisku infekciju periapikalnih lezija trima bakterijskim vrstama. U našem istraživanju su *Prevotella nigrescens* i *Propionibacterium propionicum* nađeni svaki u po jednom uzorku. Niska prevalencija izvankorijenske infekcije ovim dvjema vrstama bila je očekivana i u skladu je s navodima o niskoj prevalenciji ekstraradikalnih biofilmova (nađenih u 6 %) kod neliječenih i liječenih zuba (14). U citiranoj studiji nije nađena povezanost između biofilmova i kliničkih simptoma ili prisutnosti fistule

ic endodontic infections (17). *Pseudoramibacter alactolyticus* and *Propionibacterium propionicum* were detected in root canals of patients with failed endodontic treatment (4).

Exclusion criteria were applied to the patients that had been taking antibiotic therapy during the previous three months, due to a possible decrease in the number of anaerobic bacteria caused by antibiotic therapy. In this research, the intention was to study microbiological aspects of periapical transparencies persisting after endodontic treatment that are „closed“ i.e. not communicating with periodontium or oral cavity through caries, not adequately condensed root canal fillings, unfilled root canals, and leaking coronar restoration. Also, root fracture, sinus tract, communication with maxillary sinus, and tooth mobility indicate communication of periapical lesion with oral ecosystem, and similar cases were also excluded from our research before or during operative procedure.

It must be pointed out that we took great care about the samples in order to prevent contamination with oral bacteria. For this purpose, the rules of aseptic surgical sampling were applied. Marginal incision was performed to reflect mucoperiosteal flap and reach periapical region, because it was reported that the risk of contamination was not significantly higher when compared to submarginal incision, and significantly smaller than with Partsch incision (18). Mucosa was rinsed with 0.2% chlorhexidine-gluconate, and microbiological samples were cultivated, and although with marginal incision, 100% of the samples from bone were positive, as compared to only 20% with submarginal incision, the ratio of periapical samples positive for microorganisms did not significantly differ between the two groups, and the microorganisms cultivated from mucosa, bone and periapical tissues of the same patient differed. The authors concluded that mucoperiosteal flap reflection was not responsible for positive findings. Still, even if care is taken to avoid contamination from the mouth, it is still possible that the lesion gets infected by the intraradicular bacteria during sampling, and the positive finding of microorganisms in such samples can be reported as extraradicular infection (1). Apart from the mentioned contamination of the samples, molecular techniques such as PCR in detecting microorganisms in the samples of periapical tissue are questionable as well. Is not possible to differentiate between viable and non-viable microorganisms nor is it possible to distinguish microbes and their structural elements in phagocytes from extracellular microorganisms using the PCR method (1, 4). Therefore, although molecular methods are quite sophisticated, they do not solve the primary issue of avoiding contamination of periapical lesion during sampling.

The use of universal bacterial primer in our research revealed bacterial infection in 16.67% of the samples. Our results also suggest that there was a low incidence of periapical infection with the three bacterial species examined. In our study *Prevotella nigrescens* and *Propionibacterium propionicum* were detected in one sample each. Low prevalence of extraradicular infection with these two species was expected and is in agreement with the reported low prevalence of extraradicular biofilms (found in 6%) in the teeth with either untreated or treated root canals (14). In the cited study,

(14), kao ni u našem istraživanju. Iwu (19) je istaknuo nizak stupanj očekivanosti mikroorganizama u perzistentnim periapikalnim lezijama s obzirom na to da su to kronične infekcije, a naši rezultati to potkrepljuju. Sljedeća je pretpostavka bila da su mikroorganizmi, ako su prisutni, neravnomjerno raspoređeni u volumenu lezije, što može dati lažne negativne rezultate kada se uzorci promatraju pod svjetlosnim mikroskopom (19). No u našem istraživanju to nije bio slučaj jer smo se koristili cijelim uzorkom izljuštenog periapikalnog tkiva i dalje ga pripremali za analizu PCR-om. Gomes i suradnici (20) identificirali su *Prevotella nigrescens* češće u slučaju zuba s nekrotičnom pulpom negoli u endodontski neuspješno liječenim zubima. Ovaj rezultat, zajedno s niskim stupnjem očekivanosti izvanokorijenske infekcije, čini naš nalaz *P. nigrescens* u samo jednom uzorku očekivanim. Mikroorganizme koji pripadaju crno pigmentiranim gram-negativnim štapićima dugo se povezuje s razvojem endodontskih simptoma (21). Ipak, u nekim novijim radovima nisu nađeni dokazi za povezivanje crno pigmentiranih bakterija s razvojem simptoma, bez obzira na visoku prevalenciju tih bakterija u uzorcima gnoja iz periapikalnih apscesa (15, 22). U starijim istraživanjima često je u endodontskim infekcijama identificirana *P. intermedia*, ali je poslije utvrđeno da je kultivacijom teško razlučiti *P. intermedia* od *P. nigrescens*, no dvije je vrste lako diferencirati koristeći se PCR-om. *P. nigrescens* je prema literaturi prisutna u manjem postotku od ostalih crno pigmentiranih bakterija – od 7,5 posto do otprilike jedne trećine uzoraka (15, 22). To nije slučaj s našim uzorcima gdje je nađena u samo jednom uzorku, ali mora se istaknuti da su se uzorci u navedenim studijama uzimali iz korijenskih kanala, a unatoč nalazu *P. nigrescens* u korijenskim kanalima zuba s perzistentnim periapikalnim lezijama, ona nije bila detektirana u istraženim uzorcima gnoja (22).

U našem je istraživanju *Pseudoramibacter alactolyticus* nađen u tri uzorka, a *Propionibacterium propionicum* u jednom. U studijama o endodontskim neuspjesima, ove su vrste nađene u značajnim postotcima 11% do 50 posto (4, 23) te su uz *E. faecalis* najprevalentnije vrste u korijenskim kanalima zuba s perzistentnim periapikalnim lezijama (4). U ovim su studijama uzorci uzimani iz korijenskih kanala. Zato se rezultati ne mogu uspoređivati s našim rezultatima. Kao što je već spomenuto, mi smo našli *Pseudoramibacter alactolyticus* u trima uzorcima perzistentne apikalne lezije. Premda je postotak inficiranih uzoraka nizak, očekivan je i u skladu s rezultatima Siqueira i Rôçasa (4). Oni su istaknuli da su *P. alactolyticus* i *P. propionicum* najprevalentnije bakterijske vrste u korijenskim kanalima neuspješno liječenih zuba, nakon *E. faecalis*, a svaki ispitan uzorak sadržavao je barem jednu gram-pozitivnu bakterijsku vrstu *E. faecalis*, *P. alactolyticus* ili *P. propionicum*. Ponovno treba uzeti u obzir to da smo analizirali periapikalno tkivo, a ne uzorke iz korijenskog kanala. *Propionibacterium propionicum* fakultativni je anaerob ranije poznat kao *Arachnia propionica*. Ovaj mikroorganizam ima slične invazivne karakteristike kao *actinomyces* (3). Rodovi *Actinomyces* i *Propionibacterium* mogu uzrokovati kroničnu, granulomatoznu infektivnu bolest zvanu aktinomikoza. Ove su bakterije gram-pozitivni filamenti koji završavaju hifama, nisu ni kiseli, ni pokretni i stvaraju isprepletene filamento-

no correlation between biofilms and clinical symptoms or sinus tract presence was noticed (14), likewise in our study. Iwu (19) pointed to a low expectancy rate of microorganisms in persistent periapical lesions since they are chronic infections, and our results confirmed that fact. Further assumption was that microorganisms, if present, are not equally present in the entire volume of the lesion, which could give false negative results when the samples are examined by light microscope (19), but this was not the case in our study where we used the whole sample of enucleated periapical tissue and prepared it for further PCR analysis. Gomes et al. (20) reported that *Prevotella nigrescens* are more frequently present in the teeth with necrotic pulp than in the teeth with failing endodontic treatment. This finding along with the finding of low expectancy of extraradicular infection as such made our detection of *P. nigrescens* in only one case expected. Microorganisms belonging to black pigmented gram-negative rods have been related to the development of endodontic symptoms for quite a long time (21). Nevertheless, some more recent reports have not found evidence for relating BPB with the development of symptoms, despite high prevalences of BPB in puss samples from periapical abscessi (15, 22). Previous research frequently identified *P. intermedia* in endodontic infection, but more recent studies reported that it was hard to differentiate between *P. intermedia* and *P. nigrescens* by cultivation; however, the two species are easily differentiated using the PCR. *P. nigrescens* was reported to be present in lesser percentage than other black pigmented bacteria from 7.5 % to about one third of the samples (15, 22) unlike our samples where *P. nigrescens* was found in only one sample. Yet it needs to be emphasized that the samples in the mentioned studies were taken from root canals, and although *P. nigrescens* was detected in the root canals of the teeth with persistent periapical lesion, it was not detected in any puss sample of the cases examined (22).

In our research, *Pseudoramibacter alactolyticus* and *Propionibacterium propionicum* were detected in 3 samples and 1 sample, respectively. In the studies dealing with endodontic failures, these species were detected in significant percentages 11%-50% (4, 23) and were, apart from *E. faecalis*, the most prevalent species detected in the root canals of the teeth with persistent periapical lesion (4). In these reports, the samples were taken from root canals. Hence, these results cannot be compared to ours. As already mentioned, we detected *Pseudoramibacter alactolyticus* in 3 tissue samples of persistent apical lesions. Although the percentage of the infected samples is low it, such a result has been expected and it is in accordance with the findings of Siqueira and Rôças (4). They found that *E. faecalis*, *P. alactolyticus* and *P. propionicum* are the most prevalent species in the root canal samples of the teeth with failed endodontics, and that all of the examined samples harbored at least 1 of the gram-positive bacterial species: *E. faecalis*, *P. alactolyticus*, or *P. propionicum*. It must be pointed out that that we analysed periapical tissues rather than root canal samples. *Propionibacterium propionicum* is a facultative anaerobe formerly known as *Arachnia propionica*. This microorganism shares similar invasive characteristics as *actinomyces* (3). Genera *Actinomyces* and *Propionibacterium* can cause



zne kolonije koje se zovu sumporne granule (1). Endodontske aktinomikoze uzrokovane su *Actinomyces israelii* i *Propionibacterium propionicum*, komenzalima u usnoj šupljini. Ovi mikroorganizmi mogu uspostaviti kohezivne ekstraradikalne kolonije otporne na imunosti odgovor. One su dosljedno izolirane iz periapikalnih lezija koje nisu cijelile nakon ispravno provedenog endodontskog liječenja (1).

Uloga *Enterococcus faecalis* kao temeljnoga patogena u poslijeendodontskoj bolesti je upitna (24, 25), a vrste koje pripadaju drugim rodovima, uključujući *Prevotella*, *Propionibacterium* i *Pseudoramybacter*, također su detektirane u korijenskim kanalima prije liječenih zuba (7, 26, 27). Rôças i Siqueira (27) utvrdili su da su tijekom revizije liječenja *Propionibacterium* (52 %) i *Pseudoramibacter alactolyticus* (14 %) prevalentniji u korijenskim kanalima zuba s perzistentnim apikalnim parodontitisom od bakterije *Enterococcus faecalis* (12 %). Naši rezultati u skladu su s recentnim studijama koje dvoje o *E. faecalis* kao glavnom patogenu u postendodontskom apikalnom parodontitisu (24, 25). Štoviše, premda su neke bakterije prepoznate kao temeljni patogeni, sinergijska aktivnost cijele bakterijske zajednice interferira s domaćinovima imunostimulativnim sustavom i uzrokuje destrukciju tkiva (14, 13). Biofilm je oblik zajednice mikroorganizama pričvršćen na čvrstu površinu u fluidu koji sadržava nutrijente, u kojima su stanice mikroba ugrađene u ekstracelularni matriks u međusobnoj interakciji. Mikroorganizmi koji žive u biofilmu mogu se samoorganizirati, pružati otpor promjenama okoliša, djelovati sinergijski i odgovoriti na promjene u okolišu kao zajednica (12, 13, 14). Imajući na umu tendenciju mikroorganizama da stvaraju intraradikalne i ekstraradikalne biofilme, buduće metagenomske studije trebale bi biti usmjerene na patološki potencijal bakterijskih biofilмова, radije negoli na pojedinačni mikroorganizam, unatoč relativno malom broju bakterijskih vrsta povezanih s perzistentnim periapikalnim parodontitisom. Istraživački modeli koji se koriste postupcima kultivacije i PCR-a ne mogu otkriti interakcijske potencijale između različitih bakterijskih vrsta s obzirom na to da je teško zajedno kultivirati mnogo vrsta, a PCR ne razlikuje žive mikroorganizme od neživih mikroorganizama.

## Zaključci

Možemo zaključiti da lezije apikalnoga parodontitisa povezanog s neuspješnim endodontskim liječenjem mogu sadržavati mikroorganizme koji ne pripadaju *Actinomyces* i *Propionicum species*. Prevalencija infekcije zatvorenih lezija perzistentnoga apikalnog parodontitisa *P. nigrescens*, *P. propionicum* i *P. alactolyticus* je niska. Istraživanje koje smo provedli ne daje dovoljno podataka o povezanosti ekstraradikalne infekcije s dijabetesom melitusom i kliničkim simptomima.

## Sukob interesa

Nije bilo sukoba interesa.

a chronic, granulomatous, infectious disease called actinomycosis. These bacteria are Grampositive filaments that end in hyphae and they are non-acid, non-motile, and form intertwining filamentous colonies called "sulphur granules" (1). The endodontic infections of actinomyces are caused by *Actinomyces israelii* and *Propionibacterium propionicum*, commensals of the oral cavity. These microorganisms can establish cohesive extraradicular colonies resistant to the immune system. They are consistently isolated from the periapical lesions which did not heal after an adequate endodontic treatment (1).

The role of *Enterococcus faecalis* as a key-stone pathogen in posttreatment disease was questioned (24, 25) and the species belonging to other genera including *Prevotella*, *Propionibacterium*, and *Pseudoramybacter* have also been detected in root canals of treated teeth (7,26,27). Rôças and Siqueira (27) found that *Propionibacterium* (52%) and *Pseudoramibacter alactolyticus* (14%) were more prevalent in root canal samples of the teeth with posttreatment apical periodontitis undergoing retreatment than *Enterococcus faecalis* (12%). Our findings are in line with recent studies that have questioned the status of *E. faecalis* as the main pathogen in posttreatment apical periodontitis (24, 25). Moreover, although ceratin bacteria can be recognized as key-stone pathogens, it is the synergistic activity of the whole bacterial community that interferes with host immune defence and causes tissue destruction (14, 13). Biofilm is a form of microbial community attached to a solid surface in a nutrient-containing fluid, where the microbial cells embedded in an extracellular matrix, interact with each other. The microorganisms living in a biofilm are able to self-organize, resist environmental changes, act synergistically and respond to the changes in the environment as a community (12, 13, 14). Bearing in mind the tendency of microorganisms to form intraradicular and extraradicular biofilms, the future metagenomic studies should be oriented on the pathologic potential of bacterial biofilms rather than on a single microorganism, despite relatively few bacterial species involved in persistent periapical periodontitis. Study designs using cultivation methods and PCR cannot reveal interaction potentials between different microbial species since it is hard to co-cultivate many species, and PCR does not differentiate between viable and non viable microorganisms.

## Conclusions

We can conclude that lesions of apical periodontitis associated with failed endodontic treatment could harbor microorganisms other than *Actinomyces* and *Propionicum species*. The prevalence of infection of closed lesions of persistent apical periodontitis with *P. intermedia*, *P. propionicum* and *P. alactolyticus* is low. We have insufficient data for clearly determining extraradicular infection and its connection with diabetes mellitus and clinical symptoms.

## Conflict of Interest

None declared

**Abstract**

**Objectives:** To determine the percentage of persistent apical lesions positive for bacterial nucleic acids, to detect microorganisms difficult to cultivate in persistent apical lesions by PCR and relate them to endodontic failure, clinical symptoms and diabetes mellitus. **Materials and methods:** The samples of persistent apical lesions were collected during apicoectomy. Bacterial ubiquitous primer 16S rRNA was used to detect 16S ribosomal RNA in 36 samples. A species-specific PCR was performed with primers targeted to the bacterial 16S rRNA genes of *Prevotella Nigrescens*, *Pseudoramibacter alactolyticus*, and *Propionibacterium propionicum*. **Results:** Six samples (16.67%) were positive for bacterial ribosomal RNA. *Pseudoramibacter alactolyticus* was detected in three samples. *Propionibacterium propionicum* and *Prevotella nigrescens* were detected in one sample each. The prevalence of infection of such lesions with *P. intermedia*, *P. propionicum* and *P. alactolyticus* is low. **Conclusion:** The study we conducted gave insufficient data about extraradicular infection and its connection with diabetes mellitus and clinical symptoms. **Conclusions:** Apical lesions persisting after endodontic treatment could harbor microorganisms other than *Actinomyces* and *Propionicum* species.

Received: May 13, 2017

Accepted: July 31, 2017

**Address for correspondence**

Ana Ivanišević Malčić  
University of Zagreb  
School of Dental Medicine  
Gundulićeva 5, 10000 Zagreb, Croatia  
Phone: +385 1 4802 126; +385 99  
4030 549  
Fax: +385 1 4802 159  
aivanisevic@sfzjg.hr

**Key words**

Root Canal Preparation; Treatment Failure; periapical abscess; Bacterial RNA; 16S Ribosomal RNA; Polymerase Chain Reaction

**References**

- Nair PNR. Pathogenesis of Apical Periodontitis and the Causes of Endodontic Failures. *Crit Rev Oral Biol Med.* 2004 Nov 1;15(6):348-81.
- Nair PNR, Sjögren U, Figdor D, Sundqvist G. Persistent periapical radiolucencies of root-filled human teeth, failed endodontic treatments, and periapical scars. *Oral Surg Oral Med Oral Pathol Oral Radiol Endod.* 1999 May;87(5):617-27.
- Siqueira JF Jr. Periapical actinomycosis and infection with *Propionibacterium propionicum*. *Endod Top.* 2003;6(1):78-95.
- Siqueira JF Jr, Rocas IN. Polymerase chain reaction-based analysis of microorganisms associated with failed endodontic treatment. *Oral Surg Oral Med Oral Pathol Oral Radiol Endod.* 2004 Jan;97(1):85-94.
- Peciuliene V, Balciuniene I, Eriksen HM, Haapasalo M. Isolation of *Enterococcus faecalis* in previously rootfilled canals in a Lithuanian population. *J Endod.* 2000 Oct;26(10):593-5.
- Peciuliene V, Reynaud AH, Balciuniene I, Haapasalo M. Isolation of yeasts and enteric bacteria in root-filled teeth with chronic apical periodontitis. *Int Endod J.* 2001 Sep;34(6):429-34.
- Pinheiro ET, Gomes BP, Ferraz CC, Sousa EL, Teixeira FB, Souza-Filho FJ. Microorganisms from canals of root-filled teeth with periapical lesions. *Int Endod J.* 2003 Jan;36(1):1-11.
- Sundqvist G, Figdor D. Life as an endodontic pathogen: ecological differences between the untreated and root-filled root canals. *Endod Topics.* 2003; 6(1):3-28.
- Narayanan LL, Vaishnavi C. Endodontic microbiology. *J Conserv Dent.* 2010 Oct;13(4):233-9. doi: 10.4103/0972-0707.73386.
- Gatti JJ, Dobeck JM, Smith C, Socransky SS, Skobe Z. Bacteria of asymptomatic periradicular endodontic lesions identified by DNA-DNA hybridization. *Endod Dent Traumatol.* 2000 Oct;16(5):197-204.
- Sunde PT, Olsen I, Debelian GJ, Tronstad L. Microbiota of periapical lesions refractory to endodontic therapy. *J Endod.* 2002 Apr;28(4):304-10.
- Ricucci D, Candeiro GT, Bugea C, Siqueira JF Jr. Complex Apical Intra-radicular Infection and Extraradicular Mineralized Biofilms as the Cause of Wet Canals and Treatment Failure: Report of 2 Cases. *J Endod.* 2016 Mar;42(3):509-15.
- Wang J, Chen W, Jiang Y, Liang J. Imaging of extraradicular biofilm using combined scanning electron microscopy and stereomicroscopy. *Microsc Res Tech.* 2015 Oct;78(10):947.
- Ricucci D, Siqueira JF Jr. Biofilms and apical periodontitis: study of prevalence and association with clinical and histopathologic findings. *J Endod.* 2010 Aug;36(8):1277-88.
- Fouad AF, Barry J, Caimano M, Clawson M, Zhu Q, Carver R, Hazlett K, Radolf JD. PCR-based identification of bacteria associated with endodontic infections. *J Clin Microbiol.* 2002 Sep;40(9):3223-31.
- Kakehashi S, Stanley HR, Fitzgerald RJ. The effects of surgical exposures of dental pulps in germ-free and conventional laboratory rats. *Oral Surg Oral Med Oral Pathol.* 1965 Sep;20:340-9.
- Sundqvist G. Taxonomy, ecology, and pathogenicity of the root canal flora. *Oral Surg Oral Med Oral Pathol.* 1994 Oct;78(4):522-30.
- Tronstad L, Barnett F, Cervone F. Periapical bacterial plaque in teeth refractory to endodontic treatment. *Endod Dent Traumatol.* 1990 Apr;6(2):73-7.
- Iwu C, MacFarlane TW, MacKenzie D, Stenhouse D. The microbiology of periapical granulomas. *Oral Surg Oral Med Oral Pathol.* 1990 Apr;69(4):502-5.
- Gomes BP, Jacinto RC, Pinheiro ET, Sousa EL, Zaia AA, Ferraz CC, Souza-Filho FJ. *Porphyromonas gingivalis*, *Porphyromonas endodontalis*, *Prevotella intermedia* and *Prevotella nigrescens* in endodontic lesions detected by culture and by PCR. *Oral Microbiol Immunol.* 2005 Aug;20(4):211-5.
- van Winkelhoff AJ, Carlee AW, de Graaff J. *Bacteroides endodontalis* and other black pigmented *Bacteroides* species in odontogenic abscesses. *Infect Immun.* 1985 Sep;49(3):494-7.
- Siqueira JF Jr, Rocas IN, Oliveira JC, Santos KR. Molecular detection of black-pigmented bacteria in infections of endodontic origin. *J Endod.* 2001 Sep;27(9):563-6.
- Sundqvist G, Figdor D, Sjogren U. Microbiologic Analysis of teeth with failed endodontic treatment and the outcome of conservative re-treatment. *Oral Surg Oral Med Oral Pathol Oral Radiol Endod.* 1998 Jan;85(1):86-93.
- Kaufman B, Spangberg L, Barry J, Fouad AF. *Enterococcus* spp. in endodontically treated teeth with and without periradicular lesions. *J Endod.* 2005 Dec;31(12):851-6.
- Zoletti GO, Siqueira JF Jr, Santos KR. Identification of *Enterococcus faecalis* in root-filled teeth with or without periradicular lesions by culture-dependent and -independent approaches. *J Endod.* 2006 Aug;32(8):722-6.
- Gomes BP, Pinheiro ET, Jacinto RC, Zaia AA, Ferraz CC, Souza-Filho FJ. Microbial analysis of canals of root-filled teeth with periapical lesions using polymerase chain reaction. *J Endod.* 2008 May;34(5):537-40.
- Rôças IN, José F, Siqueira Jr. Characterization of microbiota of root canal-treated teeth with posttreatment disease. *J Clin Microbiol.* 2012 May;50(5):1721-4.