

Jonas Lorenz;<sup>1\*</sup> Markus Schlee;<sup>2\*</sup> Sarah Al-Maawi,<sup>1</sup> Poju Chia;<sup>1</sup> Robert A. Sader;<sup>1,#</sup> and Shahram Ghanaati<sup>1,#,\*</sup>

## Razina pročišćenosti alogenoga koštanog bloka

### Variant Purification of an Allogeneic Bone Block

<sup>1</sup> FORM-Lab, Zavod za oralnu, kraniofacijalnu i plastičnu kirurgiju lica, Medicinski centar Goethe sveučilišta u Frankfurtu na Majni, Njemačka  
FORM-Lab, Department of Oral, Cranio-Maxillofacial and Facial Plastic Surgery, Medical Center of the Goethe University Frankfurt, Frankfurt am Main, Germany

<sup>2</sup> Privatna ordinacija, Forchheim, Goethe University, Frankfurt, Njemačka  
Private Practice, Forchheim, Goethe University, Frankfurt, Germany

<sup>#,\*</sup> Podjednaka zastupljenost autora  
Equally contributed

#### Sažetak

**Svrha:** Ovaj kratak tekst izvještava o histološkoj analizi sastava komercijalno raspoloživih alogeničkih koštanih blokova Maxgraft®. **Materijali i metode:** Na temelju objavljenih histoloških metoda prazni uzorci alogeničkih koštanih blokova Maxgraft® dekalificirani su, dehidrirani i uloženi u parafin prije histološkog i histokemijskog bojenja. Nakon toga na prezeza su se procjenjivala obilježja materijala, poput strukture koštanoga matriksa i druge komponente, uključujući kolagen ili stanice/stanične ostatke. **Rezultati:** Uočeno je da ovi koštani blokovi imaju trabekularnu strukturu s lamelnom podorganizacijom. Dodatno su nađeni i stanični ostatci unutar lakuna osteocita i na vanjskim površinama trabekula zajedno s ostatcima intertrabekularnog masnog i vezivnog tkiva, te kolagene strukture, vezivno-tkivne stanice i stanični ostatci. **Zaključak:** U skladu s dosadašnjim istraživanjima, podatci iz ovoga teksta pokazuju da neke od certificiranih tehnika pročišćavanja ne omogućuju proizvodnju alogeničkoga materijala bez organskih stanica i tkivnih komponenata.

**Zaprimljen:** 15. svibnja 2017.  
**Prihvaćen:** 3. lipnja 2017.

#### Adresa za dopisivanje

Shahram Ghanaati, MD, DDS  
Medical Center of the Goethe University Frankfurt  
Department for Oral, Cranio-maxillofacial and Facial Plastic Surgery  
FORM-Lab, Theodor-Stern-Kai 7  
D-60590 Frankfurt/Main, Germany  
tel.: +49-69-6301-5879  
faks: +49-69-6301-5644  
Shahram.ghanaati@kgu.de

#### Gljučne riječi

homologna transplantacija; nadomjestci za kost; biokompatibilni materijali; tehnika dekalifikacije; isušenje

#### Uvod

U uporabi su mnogobrojne različite alogene i ksenogene koštane zamjene jer ti materijali imaju pozitivan regenerativni potencijal zbog njihova *privodnog* sastava i koštane strukture slične autografnom presađivanju (1, 2). Prije njihova kliničkog korištenja, donorsko tkivo mora se očistiti i osloboditi od svih imunogenih aktivnih komponenti, poput različitih vrsta stanica i proteina matriksa (3). Da bi se to postiglo, razvijene su tehnike pročišćavanja s različitim fizičkim i/ili kemijskim metodama. Tako većina tvrtki za proizvodnju materijala ima vlastite metode pročišćavanja koje zadovoljavaju glavne kriterije, tj. standarde poput ISO 10993 (4, 5). Ipak, na temelju korištenja histokemijskih metoda bojenja za otkrivanje anorganskoga matriksa i staničnih komponenti ili komponenti organskoga matriksa, predstavili smo mnogobrojne varijacije među različitim komercijalnim koštanim blokovima, uključujući dva alogena i tri ksenogena (4). Osim toga, istaknuli smo nedosljednost između informacija proizvođača koštanih blokova i njihova analiziranog sastava. Sveukupno, rezultati ovih istraživanja otkrili su da tri od pet koštanih blokova sadržavaju organske/stanične ostatke.

#### Introduction

Numerous allogeneic and xenogeneic bone substitutes of different kinds have been introduced, since these classes of materials could exhibit a favorable regenerative potential based on their "natural" composition and bone tissue structure comparable to autografts (1, 2). Before their clinical application, the donor tissue must be purified and freed from all immunologically effective components such as the different cell types and matrix proteins (3). To accomplish this, a variety of purification techniques with different physical and/or chemical methods have been developed. In this context, most of the material companies have introduced their own purification methods, which follow relevant guidelines, i.e., standards such as the ISO 10993 (4, 5).

However, before using general histochemical staining methods to detect the inorganic matrix and cellular or organic matrix components, we had previously found wide variations among different commercially available bone blocks (4). Furthermore, we found some discrepancies between the manufacturer's information and the composition of the bone

Svrha ovog teksta bila je analizirati (ultra-)strukture komercijalno raspoloživih alogeničkih koštanih blokova Maxgraft®. Obavili smo njihovu strukturnu analizu kako bismo raščlanili (ultra-)strukturu kalcificiranoga koštanog matriksa i procijenili prisutnost ostalih komponenata poput kolagena i organskih/staničnih ostataka.

## Materijali i metode

Tri uzorka komercijalno raspoloživih alogeničkih koštanih blokova Maxgraft® histološki su pripremljeni i pregledani radi procjene njihova sastava, kao što je već najavila naša grupa (4). Zbog određivanja kvalitete pročišćivanja posebno smo se usredotočili na otkrivanje mogućih organskih komponenata. Dodatno smo usporedili podatke proizvođača i rezultate istraživanja.

### Maxgraft®

Maxgraft® (Botiss biomaterials GmbH, Berlin, Njemačka) alogeni je mineralizirani zamjenski koštani blok dobiven od kosti glave femura živih humanih donora iz njemačkih, austrijskih i švicarskih bolnica (6). Koštani blokovi dobiveni su od certificirane neprofitne organizacije *Cells + Tissuebank Austrija*, ustanove koju nadzire austrijsko Ministarstvo zdravstva (6, 7). Pročišćivanje koštanoga tkiva usklađeno je s odgovarajućim europskim smjernicama i austrijskim propisom o sigurnosti tkiva (6, 7). Za ovaj postupak pročišćivanja tvrdi se da su ga *validirane neovisne institucije* i austrijsko Ministarstvo zdravstva (7).

Postupak pročišćivanja, tzv. *C+TBA postupak*, opisan je potanko na stranicama proizvođača (8). Ukratko, tvrdi se da je to iznimno siguran i kvalitetan postupak te da su se pritom poštovali najviši standardi kvalitete koji se koriste u inaktiviranju virusa i bakterija (7, 8).

Postupak pročišćivanja uključuje različite fizikalne i kemijske procese (8). Tvrdi se da se primjenjuje tehnika na temelju ultrazvuka za uklanjanje krvi, stanica i staničnih komponenti, a koja bi uklonila najviše masnog tkiva kao fizikalna metoda. Dodatno se postupci kemijskoga i oksidativnoga čišćenja dietilnim eterom i etanolom različitog trajanja upotrebljavaju za inaktivaciju, kako patogena poput virusa i bakterija, tako i nekolagenih proteina (8).

Sljedeći postupak oksidativnog pročišćivanja trebao bi ukloniti topive proteine denaturacijom potencijalnih antigena (8). Na kraju se primjenjuje gama-zračenje za liofilizaciju i sterilizaciju sa svrhom očuvanja prirodne strukture tkiva (8). Nisu dane informacije o sastavu koštanoga bloka, tako da nisu opisani ni (ultra)struktura koštanoga matriksa ni druge komponente, poput kolagena specifičnog za koštano tkivo.

### Histološka priprema koštanih blokova

Tri uzorka decalcificirana su u *tris puferviranoj* 10-postotnoj EDTA-i (Carl Roth, Karlsruhe, Njemačka), zatim su dehidrirani u nizu alkohola uzlaznih koncentracija te nakon ksilola uklopljeni u parafin (kako je prethodno opisano) (4, 9 – 11).

blocks as analyzed subsequently. Altogether, the results obtained in this study revealed that three out of five bone blocks contained organic/cellular remnants.

The aim of this short communication was to analyze the (ultra-) structure of commercially available Maxgraft® allogeneic bone block. Specifically, we performed a structural analysis of the bone block to analyze the (ultra-) structure of the calcified bone matrix and to investigate the presence of other components such as collagen and organic/cellular remnants.

## Materials and Methods

Three samples of a commercially available Maxgraft® allogeneic bone block were histologically prepared and examined to evaluate their composition as previously published by our group (4). We particularly focused on the detection of possible organic components to establish their purification quality. Additionally, the manufacturer's information and the study results were compared.

### Maxgraft®

Maxgraft® (botiss biomaterials GmbH, Berlin, Germany) is an allogeneic cancellous bone substitute block derived from the bone of femoral heads of living human donors from German, Austrian and Swiss hospitals (6). The bone blocks are processed by the Cells + Tissue bank Austria, a certified and audited non-profit organization that is regulated by the Austrian Ministry of Health (6, 7). The purification of the bone tissue is in accordance with the respective European Directives and the Austrian Tissue Safety Act (6, 7). This purification process is stated to be "validated by independent institutes" and by the Austrian Health Ministry (7).

The purification process, the "C+TBA process", is described in more detail on the manufacturer's homepage (8). Briefly, it is stated to be a highly secure quality process that is in compliance with the highest quality standards that are employed when inactivating viruses and bacteria (7, 8). This purification process includes different physical and chemical purification steps (8). It is stated that an ultrasonic-based removal of blood, cells and tissue components is applied, which should predominantly remove adipose tissue, as a physical method. Additionally, chemical and oxidative cleaning steps by means of diethyl ether and ethanol at different durations were employed to inactivate both pathogens, such as viruses and bacteria, and also non-collagen proteins (8). Furthermore the oxidative purification step should eliminate soluble proteins by denaturation and potential antigens (8). Finally, lyophilization and sterilization via gamma irradiation were applied to preserve the natural tissue structure (8). No information was given about the composition of the final bone block, so that neither the (ultra-) structure of the bone matrix nor other components, such as bone tissue-specific collagen, are described.

### Histological preparation of the bone blocks

Three material samples were initially decalcified in Tris-buffered 10% EDTA (Carl Roth, Karlsruhe, Germany), dehydrated in a series of increasing alcohol concentrations followed by xylol application and embedded in paraffin as

Histološki rezovi od 3 do 5 mm dobiveni su na rotacijskom mikrotomu (Leica RM2255, Wetzlar, Njemačka).

Korištena su tri histokemijska bojenja, uključujući hematoxinsin i eosin (HE), Masson-Goldnerov trikrom i Sirius red te Giemsa. Dodatni presjek obojen je za histokemijsku metodu otkrivanja tartarat-rezistentne fosfataze (TRAP) da se identificiraju osteoklasti. Za kontrolu kvalitete TRAP bojenja korišten je presjek zdrave kosti.

### Histološka analiza

Histološka analiza obavljena je na koštanim blokovima kao što je opisano (4, 9 – 11). Ukratko, histološki prerezi koštanih zamjena procijenjeni su za svojstva materijala poput strukture koštanoga matriksa i drugih komponenata, uključujući i kolagen ili stanice/stanične ostatke. Ovaj dio neovisno su obavila dva autora (JL i SG) svjetlosnim mikroskopom (Nikon Eclipse 80i, Tokio, Japan). Za dokumentiranje histoloških slika korištena je digitalna kamera DS-Fi1 i digitalni slide controler DS-L2 (oboje Nikon, Tokio, Japan).

### Rezultati

Histološkom analizom otkrivena je trabekularna struktura anorganskoga koštanog matriksa Maxgraft® (slika 1. A). Unutar trabekularnih prostora otkriveno je nešto anorganskih fragmenata koštanoga matriksa (slika 1. A). Anorganski koštani matriks imao je i lamelarnu substrukturu (slika 1. B). Unutar lakuna osteocita anorganskoga koštanog matriksa uočene su stanice ili stanični ostatci (slika 1. B). Osim toga, na trabekularnim površinama koštanih blokova u kojima su uočene višejezgrene i jednojezgrene stanice (slika 1. C). Višejezgrene stanice nisu se pozitivne obojile za TRAP (podatci nisu prikazani). Dodatno, unutar trabekularnih prostora nađene su strukture nalik na masno tkivo (slika 1. D). Na pojedinim mjestima bilo je i ostataka nekadašnjeg intratrabekularnoga vezivnog tkiva sastavljenog od izvanstaničnog matriksa i stanica ili staničnih ostataka (slika 1. E).

### Rasprava

Pročišćavanje alogenih i ksenogenih biomaterijala zbog potencijalno imunogenih komponenata, poput donorskih stanica, bakterija i virusa, vitalno je važna za njihovu uspješnu i sigurnu uporabu (3). Na raspolaganju su nam različiti zamjenski materijali za kost na temelju humanih i životinjskih donorskih tkiva. Ta se tkiva prerađuju raznim metodama pročišćavanja koje jamče njihovu sigurnu kliničku primjenu. U ovom kontekstu, proizvođači garantiraju da njihove različite metode pročišćavanja slijede upute Međunarodne organizacije za standardizaciju (International Organization for Standardization – ISO) ili nacionalne i međunarodne smjernice koje je potrebno zadovoljiti da bi dobili odobrenje svojih ministarstava zdravstva.

Nečistoće unutar alogenih i ksenogenih biomaterijala već su opisane u radu naše grupe i ostalih istraživača (4, 12). U

previously described (4,9-11). Histological sections of 3-5 mm thickness were obtained using a rotation microtome (Leica RM2255, Wetzlar, Germany).

Three histochemical stains were used, including hematoxylin and eosin (HE), Masson-Goldner's trichrome and Sirius red and Giemsa. An additional section was stained using a histochemical method to detect tartrate-resistant acid phosphatase (TRAP) to identify osteoclasts. A bone section was used to control the quality of the TRAP staining method.

### Histological analysis

The histological analysis of the bone blocks was conducted as previously described (4, 9-11). Briefly, the histological bone substitute slides were evaluated for their material characteristics, such as the bone matrix structure and other components, including collagen or cells/cell remnants. This procedure was performed independently by two authors (JL and SG) using a light microscope (Nikon Eclipse 80i, Tokyo, Japan). A Nikon DS-Fi1 digital camera and a DS-L2 digital sight control unit (both: Nikon, Tokyo, Japan) were also used to obtain histological photomicrographs.

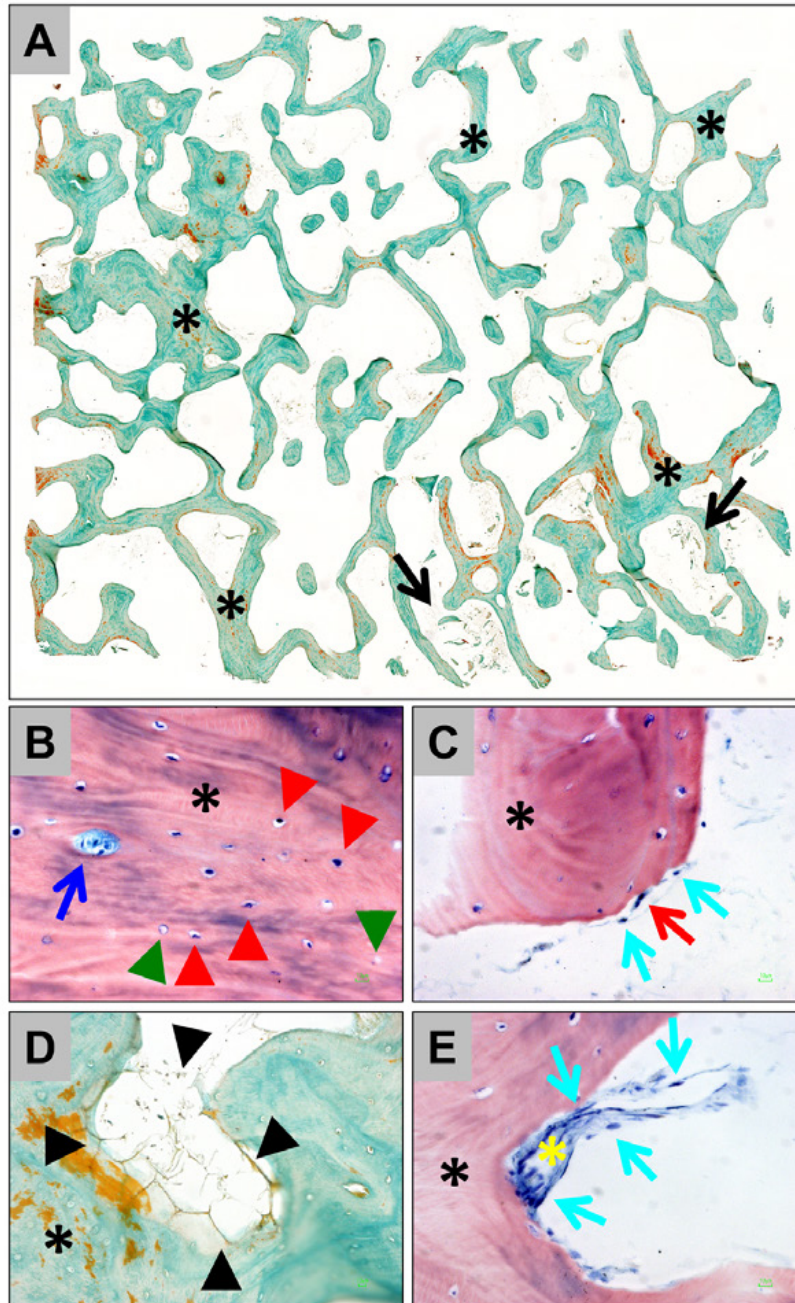
### Results

The histological analysis revealed that the inorganic bone matrix of the Maxgraft® bone block exhibited a trabecular structure (Figure 1A). Some inorganic bone matrix fragments were detected within the trabecular interspaces (Figure 1A). The inorganic bone matrix also exhibited a lamellar substructure (Figure 1B). Cells or cell remnants were observed within the osteocyte lacunae throughout the inorganic bone matrix (Figure 1B). Only a few lacunae were free of cells or cell remnants (Figure 1B). Furthermore, mononucleate and multinucleate cells were sporadically observed at the trabecular surfaces of the bone blocks (Figure 1C). The multinucleate cells did not express tartrate-resistant acid phosphatase (TRAP) (data not shown). Additionally, fatty tissue-like structures were apparent within the trabecular interspaces (Figure 1D). Also, the remnants of the former intertrabecular connective tissue were occasionally found, comprising both extracellular matrix and cells or cell remnants (Figure 1E).

### Discussion

The use of purifying allogeneic or xenogeneic biomaterials from potentially immunogenic components, such as donor cells, bacteria and viruses, is vital for their successful and safe application (3). A variety of different bone substitute materials based on both human and animal donor tissue is available. They are processed by different purification methods, which are all guaranteed as safe for clinical application. In this context, manufacturers guarantee that their different purification methods follow guidelines, such as the ones set by the International Organization for Standardization (ISO) or the national and international guidelines that are required for their approval by different ministries of health.

However, the presence of impurities within allogeneic and xenogeneic biomaterials could already be demonstrated by our workgroup and other researchers (4, 12). In this



**Slika 1.** Histološke slike alogernih koštanih blokova Maxgraft® s fokusom na (ultra-)strukturu i sastav; (A) poprečni presjek koštanoga bloka pokazuje trabekularnu strukturu anorganskoga koštanog matriksa (crna zvjezdica); fragmenti koštanoga matriksa (crne strjelice) mogu se uobičajeno uočiti u međuprostorima trabekularnih fragmenata (Masson-Goldnerovo bojenje, *total scan*, 100 x povećanje); (B) koštani matriks (zvjezdica) ima lamelarni podraspored; u većini lakuna osteocita nađene su stanice i stanični ostatci (crvene kratke strjelice), a samo je manji dio lakuna bio prazan (zelene kratke stanice); stanice/stanični ostatci i ekstracelularni matriks također su bili u Haversovim kanalima (plave strjelice) (Giemsovo bojenje, 400 x povećanje, mjerilo = 10 μm); (C) na vanjskim površinama koštanoga matriksa (zvjezdica) identificirane su stanice ili stanični ostatci (strjelice), a dodatno su otkrivene jednojezgrene (cijanske strjelice), višezjgrene (crvene strjelice) (Giemsovo bojenje, 400 x povećanje, mjerilo = 10 μm); (D) i (E) unutar trabekularnih prostora uočavaju se strukture poput masnoga tkiva (crne kratke strjelice u D) i vezivno-tkivni ostatci sa stanicama ili staničnim ostacima (cijanske strjelice u E) i izvanstanični matriks (žute zvjezdice u E) (koštani matriks = zvjezdica) (D: Masson-Goldnerovo bojenje, 200 x povećanje; E = Giemsovo bojenje, 400 x povećanje, mjerilo = 10 μm).

**Figure 1** Histological images of the Maxgraft® allogeneic bone block with a focus on its (ultra-) structure and composition. (A) A cross-section of the bone block illustrates the trabecular structure of the inorganic bone matrix (black asterisks). Fragments of bone matrix (black arrows) can be regularly observed within the interspaces of the trabeculae fragments (Masson Goldner-staining, “total scan”, 100 x magnification). (B) The bone matrix (asterisk) exhibits a lamellar sub-arrangement. In most of the osteocyte lacunae cells or cell remnants (red arrowheads) were found with only a few empty lacunae (green arrowheads). Cells/cell remnants and extracellular matrix are also apparent in the Haversian channels (blue arrow) (Giemsa-staining, 400x magnification, scale bar = 10 μm). (C) At the outer surfaces of the bone matrix (asterisks), cells or cellular remnants are identified (arrows). In addition to mononucleated cells (cyan arrows), multinucleated cells (red arrow) are detected (Giemsa-staining, 400x magnification, scale bar = 10 μm). (D) and (E) Within the trabecular interspaces, fatty-like tissue structures (black arrowheads in D) and connective tissue-like strands include both cells or cellular remnants (cyan arrows in E) and extracellular matrix (yellow asterisk in E) (bone matrix = asterisk) (D: Masson-Goldner-staining, 200x magnification; E = Giemsa-staining, 400x magnification, scale bars = 10 μm).

ovom kontekstu je pet komercijalnih alogeničkih ili ksenogeničkih koštanih blokova analizirano standardnim histološkim metodama, s fokusom na (ultra-) strukturu i otkrivanje staničnih ili organskih komponenata matriksa. Usporedili smo opis sastava materijala proizvođača s našim histološkim rezultatima. Zanimljivo, u tri od pet koštanih blokova stanice otkrili smo stanice ili stanične ostatke, što upućuje na to da ne zadovoljava učinkovitost pročišćivanja ovih materijala. Različitim metodama pročišćivanja analizirani koštani blokovi raspoređeni su u četiri skupine. Ova klasifikacija ima raspon od potpunog uspjelog pročišćivanja koštanoga matriksa s gubitkom lamelarne strukture, do materijala koji sadržavaju i koštani matriks s izvornom lamelarnom strukturom i kolagenom strukturom koštanoga tkiva i stanicama ili staničnim ostacima. U ovom su istraživanju alogenički koštani blokovi Maxgraft® analizirani istom histološkom metodom. Rezultati pokazuju da imaju trabekularnu strukturu s lamelarnom podorganizacijom. Pronađeni su stanični ostatci unutar lakuna osteocita i na vanjskim površinama trabekula, tj. bivši osteoblasti i osteoklasti zajedno s ostacima masnog i vezivnog tkiva kao kolagenih struktura te stanica i staničnih ostataka vezivnog tkiva. Usporedbom navedenih podataka proizvođača i onih dobivenih u našem istraživanju, ustanovili smo da primijenjena metoda pročišćivanja omogućuje očuvanje trabekularne strukture humanoga donorskog tkiva, uključujući i lamelarnu substrukturu. Pronađena su i nepodudaranja u navodima proizvođača i rezultatima našeg istraživanja kad je riječ o prisutnosti staničnih ostataka koji su trebali biti uklonjeni naizmjeničnim ispiranjem dietil-eterom (8). Očito je nemoguće ukloniti sve intra- i ekstrabekularne stanične ostatke iz donorskoga tkiva, što može biti, među ostalim, posljedica nedovoljnog prodora otapala unutar tvrde mineralizirane strukture. Ovi rezultati, kao npr. prisutnost stanica i staničnih ostataka u Maxgraftovim® koštanim blokovima, mogla bi biti važna za kliničku primjenu ove zamjene za kost, jer su istraživanja za procjenu transplantacije ksenogenoga tkiva pokazala da razni ostatci mogu potaknuti nefiziološku proupalnu tkivnu reakciju (13–16). Sveukupno ovi rezultati pokazuju da bi se Maxgraftovi® koštani blokovi trebali uvrstiti u četvrtu skupinu koja uključuje koštane blokove s najvišim udjelom ostataka, kao i Puros® Allograft Spongiosa i OsteoBio® Sp koštani blokovi prema ranije objavljenom istraživanju naše grupe (4). Konačno, ovo istraživanje ponovno pokazuje da korištenje različitih metoda pročišćivanja za koštane zamjenske materijale na temelju njihova sastava može rezultirati pojavom ostataka različitih stanica i staničnih ostataka. Ovo su ipak samo histološki nalazi opisanih tehnika i potrebna su klinička istraživanja za dokazivanje utjecaja staničnih ostataka na klinički rezultat nakon primjene ovih specifičnih materijala. Nema podataka koji je stupanj pročišćivanja potreban za sigurnu kliničku primjenu ovih koštanih zamjena. Također je važno spomenuti klinički izvještaj Prussa i suradnika koji su izvijestili o uspješnoj kliničkoj primjeni različitih alogeničkih tkivnih transplantata steriliziranih parom octene kiseline i etanolom, no bez podataka o mogućoj tkivnoj reakciji (17). Treba ipak istaknuti da ovdje opisane histološke metode mogu prikazati samo postojeće stanične ostatke. Unutar ograničenja tih metoda, na pi-

context, five commercially available allogeneic or xenogenic bone blocks were analyzed with widely available histological methods, with a focus on (ultra-) structure and detection of cellular or organic matrix components. Additionally, we compared the manufacturer's description of the material composition with our histological results. Interestingly, the results of our analyses revealed that three out of the five bone blocks contained cells or cell remnants, which suggests that much care has to be given to material processing or the efficacy of the methods used to purify these materials. Based on different purification results, the analyzed bone blocks have been classified into four different groups. These classifications ranged from a complete purification of the bone matrix with a loss of its lamellar structure to materials that contained both bone matrix with its origin lamellar structure and collagenous structures of the bone tissue as well as cells or cellular remnants.

In the present study, the allogeneic Maxgraft® bone block was analyzed using the same histological methods. The results demonstrate that this bone block exhibits a trabecular structure with a lamellar sub-organization. In addition, cellular remnants within the osteocyte lacunae and at the outer trabecular surfaces, i.e. former osteoblasts and osteoclasts, together with remnants of the former inter-trabecular adipose and connective tissue, i.e., collagenous structures and connective tissue cells or cell remnants were detected.

A comparison of the results of our analysis and the manufacturer's information revealed that the applied purification method preserved the trabecular structure of human donor tissue, including the lamellar sub-organization. However, the manufacturer's description and our results differed regarding the presence of cellular organic remnants, which should have been eliminated by alternating solvents for rinsing, which means using diethyl ether ethanol (8). Obviously, it is not possible to remove all intra- and extra trabecular cellular remnants from the donor tissue, which occurs due to an inadequate access of the solvents into hard mineral structure amongst others.

These results, i.e., the presence of the remaining cells or cellular remnants in the Maxgraft® bone block, could be of great importance for clinical applications of this bone substitute, since some studies assessing the transplantation of xenogenic tissue have demonstrated that different types of remnants can induce non-physiological pro-inflammatory tissue responses (13-16). Altogether, our results suggest that the Maxgraft® block should be categorized within group 4, which includes bone blocks with the highest levels of remnants, such as the Puros® Allograft Spongiosa and the OsteoBio® Sp bone blocks according to a previously published study by our group (4). Finally, the results of the present study again show that the use of different purification methods could lead to different bone substitute materials based on their composition, i.e. the occurrence of different cells or cellular remnants. However, the abovementioned techniques are histological findings. Therefore, further clinical studies are needed to investigate into the relevance of cellular remnants for clinical outcomes after the application of this specific material. There are no data in the available literature about the

tanje o vitalnosti ostataka, ne može se odgovoriti korištenjem ove metodologije. Zato potencijalni imunosni odgovor unutar ljudskog organizma treba istražiti imunološkim metodologijama u kliničkom okruženju, jer se postavlja pitanje imaju li uočeni stanični ostatci ikakav utjecaj na postupak integracije ovog tipa koštane zamjene na proces cijeljenja. Do danas nije objašnjen konačni utjecaj nedovoljnog pročišćivanja na klinički rezultat primjene materijala koštanih zamjena. No radi osiguranja kvalitete materijala nehomogenoga koštanog presatka, teško je interpretirati etiologiju komplikacija jer ne odgovaraju na pitanje je li se neuspjeh dogodio zbog tehnike ili primijenjenog materijala.

### Zaključak

U ovom istraživanju analizirana je histološka struktura komercijalnoga koštanog bloka, a bila je usredotočena na utvrđivanje sastava, posebno na izgled stanica ili staničnih ostataka. Rezultati pokazuju da su ispitivani blokovi trabekularne strukture s lamelarnom suborganizacijom, uz ostatke stanica unutar lakuna osteocita i na vanjskim površinama trabekula, zajedno s ostacima intertrabekularnoga masnog i vezivnog tkiva, tj. kolagene strukture i ostatke vezivnotkivnih stanica. Svi ovi rezultati upućuju na to da bi klinička primjena trebala pokazati do koje su mjere važni dobiveni rezultati klinički.

### Zahvala

Autori zahvaljuju Vereni Hoffmann za izvrsnu tehničku pomoć. Ovo istraživanje financirali su isključivo autori.

### Sukob interesa

Autori izjavljuju da nisu bili u sukobu interesa.

degree of purification that is necessary for safe clinical application of such bone substitutes. In this context, it is important to note that a clinical report has been published by Pruss and colleagues that reports on successful application of different kinds of allogeneic tissue transplants sterilized, also, by a mixture of peracetic acid and ethanol but without presenting any data concerning the tissue reaction (17).

However, it has to be stated that histological methodology, which has been described in this paper, can only show the presence of cellular remnants. Within the limit of present methods, the question about the vitality of the remnants cannot be answered by this methodology. Therefore, a potential immunologic response within the human organism needs to be investigated by immunologic methodologies in a clinical setting, as the question arises if the observed cellular remnants have any influence on the integration process of such bone substitute materials and the healing process. To date, the final impact of insufficient purification on the clinical performance of bone substitute materials is still unresolved. However, the process of quality insurance of non-homogeneous bone graft materials makes interpretation of etiology of complications difficult and, also, calls into question the validity of interpretation of failure, technique or material.

### Conclusion

In the present study, the structure of a commercially available allogeneic bone block was histologically analyzed, with the analysis particularly focused on its composition, including the appearance of cell or tissue remnants. The results demonstrate that this bone block exhibits a trabecular structure with lamellar sub-organization that harbors cellular remnants within the osteocyte lacunae and at the outer trabecular surfaces with remnants of the former inter-trabecular fatty and connective tissue, i.e., collagenous structures and connective tissue cells or cell remnants. In conclusion, clinical application will have to confirm the relevance of the results obtained in this study.

### Acknowledgments

The authors would like to thank Ms. Verena Hoffmann for her excellent technical assistance. This research was funded solely by the authors' own research funds.

### Conflict of Interest

The authors declare no conflict of interest.

**Abstract**

**Objective:** This short communication reports on a histological analysis of the composition of the commercially available Maxgraft® allogeneic bone block. **Materials and Methods:** Based on previously published, easily applicable histological methods, blank samples of the Maxgraft® allogeneic bone block have been decalcified, dehydrated and embedded in paraffin before histological and histochemical staining. Afterwards, the slides were evaluated for their material characteristics, such as the bone matrix structure and other components, including collagen or cells/cell remnants. **Results:** The results show that this bone block exhibits a trabecular structure with lamellar sub-organization. Additionally, cellular remnants within the osteocyte lacunae and at the outer trabecular surfaces reside together with remnants of the former inter-trabecular fatty and connective tissue, i.e., collagenous structures and connective tissue cells or cell remnants. **Conclusion:** Consistent with a previous study on this topic, the data presented here demonstrate that some of the certified purification techniques might not allow for the production of allogeneic materials free of organic cell and tissue components.

Received: May 15, 2017

Accepted: June 3, 2017

**Address for correspondence**

Shahram Ghanaati, MD, DDS  
 Medical Center of the Goethe  
 University Frankfurt  
 Department for Oral, Cranio-  
 maxillofacial and Facial Plastic Surgery  
 FORM-Lab, Theodor-Stern-Kai 7  
 D-60590 Frankfurt/Main, Germany  
 Tel.: +49-69-6301-5879  
 Fax: +49-69-6301-5644  
 Shahram.ghanaati@kgu.de

**Key words**

Transplantation, homologous; Bone  
 Substitutes; Biocompatible Materials;  
 Decalcification Technique; Desiccation

**References**

- Tomford WW. Bone allografts: past, present and future. *Cell Tissue Bank* 2000;1(2):105-9.
- Simion M, Fontana F. Autogenous and xenogeneic bone grafts for the bone regeneration. A literature review. *Minerva Stomatol* 2004;53(5):191-206.
- Gilbert TW, Sellaro TL, Badylak SF. Decellularization of tissues and organs. *Biomaterials* 2006; 27(19):3675-83.
- Ghanaati S, Barbeck M, Booms P, Lorenz J, Kirkpatrick CJ, Sader RA. Potential lack of "standardized" processing techniques for production of allogeneic and xenogeneic bone blocks for application in humans. *Acta Biomater* 2014;10(8):3557-62.
- Schuh JC. Medical device regulations and testing for toxicologic pathologists. *Toxicol Pathol* 2008; 36(1):63-9.
- maxgraft, maxgraft bone ring, maxgraft bonebuilder – information brochure. Retrieved February 12, 2016, from <https://www.botiss.com/sites/default/files/botiss-brochure-maxgraft.pdf>
- Cells + Tissuebank Austria. Retrieved February 12, 2016, from <http://www.botiss-bonebuilder.com/en/content/cells-tissue-bank-austria-0>
- C+TBA Process. Retrieved February 12, 2016, from <https://www.botiss-bonebuilder.com/en/content/ctba-process>
- Barbeck M, Najman S, Stojanović S, Mitić Ž, Živković JM, Choukroun J, Kovačević P, Sader R, James Kirkpatrick C, Ghanaati S. Addition of blood to a phylogenetic bone substitute leads to an increased *in vivo* vascularization. *Biomed Mater* 2015;10(5):055007.
- Barbeck M, Dard M, Kokkinopoulou M, Markl J, Booms P, Sader RA, Kirkpatrick CJ, Ghanaati S. Small-sized granules of biphasic bone substitutes support fast implant bed vascularization. *Biomater* 2015;5(1):e1056943.
- Ghanaati S, Barbeck M, Lorenz J, Stuebinger S, Seitz O, Landes C, Kovács AF, Kirkpatrick CJ, Sader RA. Synthetic bone substitute material comparable with xenogeneic material for bone tissue regeneration in oral cancer patients: First and preliminary histological, histomorphometrical and clinical results. *Ann Maxillofac Surg* 2013;3(2):126-38.
- Fretwurst T, Spanou A, Nelson K, Wein M, Steinberg T, Stricker A. Comparison of four different allogeneic bone grafts for alveolar ridge reconstruction: a preliminary histologic and biochemical analysis. *Oral surgery, oral medicine, oral pathology and oral radiology* 2014;118,424–31.
- Chappard D, Fressonnet C, Genty C, Baslé MF, Rebel A. Fat in bone xenografts: importance of the purification procedures on cleanliness, wettability and biocompatibility. *Biomaterials* 1993;14(7):507-12.
- Manfredi AA, Capobianco A, Bianchi ME, Rovere-Querini P. Regulation of dendritic- and T-cell fate by injury-associated endogenous signals. *Crit Rev Immunol* 2009;29(1):69-86.
- Keane TJ, Londono R, Turner NJ, Badylak SF. Consequences of ineffective decellularization of biologic scaffolds on the host response. *Biomaterials* 2012;33(6):1771-81.
- Brown BN, Valentin JE, Stewart-Akers AM, McCabe GP, Badylak SF. Macrophage phenotype and remodeling outcomes in response to biologic scaffolds with and without a cellular component. *Biomaterials* 2009;30(8):1482-91.
- Pruss A, Perka C, Degenhardt P, Maronna U, Büttner-Janitz K, Paul B, Müller K, Klumpp C, Bruck JC, Von Versen R. Clinical efficacy and compatibility of allogeneic avital tissue transplants sterilized with a peracetic acid/ethanol mixture. *Cell Tissue Bank*. 2002;3(4):235-43.